

Comparison of the Conventional Band and Loop Space Maintainers with Modified Space Maintainers: A Split-mouth Randomized Clinical Trial

Manisha Tyagi¹, Vivek Rana², Nikhil Srivastava³, Noopur Kaushik⁴, Elizabeth Moirangthem⁵, Vidisha Gaur⁶

ABSTRACT

Aim and background: Space maintainers (SMs) are used to preserve space created by premature loss of primary teeth. The most commonly used band and loop (B&L) SMs have several demerits, e.g., non-functional, poor gingival health, limited survival, laboratory work for fabrication and multi-sitting procedure, etc. This study aimed to compare the efficacy of conventional B&L SMs with conventional tube and loop (CTL), bonded tube and loop (BTL) and bonded B&L in terms of gingival health, survival time, and patients' and parents' satisfaction.

Materials and methods: Fifteen children between 4 years and 8 years of age with at least two fresh extraction sites of primary molars contra- or bilaterally in each child (total 30 fresh extraction sites) were included in the study. Conventional B&L on one site while bonded loop (BL)/CTL or BTL on the other site were delivered, based on random allocation. An evaluation was done at 1st, 3rd, 6th, and 9th months for survival time, gingival health, and patients'/parents' satisfaction. Results were statistically analyzed using independent t-test and Chi-square test under SPSS version 20.0 software.

Results: 100% B&L and CTL while only 60% BL and 80% BTL survived till the end of the study. For gingival health, statistically significant differences were obtained at 1st, 3rd, 6th, and 9th month's intervals ($p < 0.05$) when CTL was compared with B&L, BL, and BTL. In terms of patients' acceptance, all the SMs were well accepted by the patients. However, on the intergroup comparison, patients' acceptance was higher with bonded SMs.

Conclusion: Conventional tube and loop SMs were found to be most efficacious in terms of survival time, gingival health, and patients' satisfaction.

Clinical significance: To find a better alternative for the conventional B&L SMs.

Keywords: Band and loop, Bonded space maintainer, Nikhils appliance, Space maintainers, Tube and loop.

International Journal of Clinical Pediatric Dentistry (2021): 10.5005/jp-journals-10005-2046

INTRODUCTION

The importance of primary dentition for a child's growth and development along with the guidance and eruption of permanent teeth is well documented in the literature. Midline shift, space loss, impacted or ectopic eruption of a permanent successor, crowding, etc., are some of the unfavorable sequelae of premature loss of primary teeth. Hence, the space created by premature loss of primary tooth needs to be preserved to maintain the integrity of dentition till the eruption of their permanent successor. Therefore, maintaining space during the period of primary and mixed dentition is important for masticatory efficiency, proper space for successors to erupt, and to maintain the vertical dimension.

Space maintainers (SMs) are the appliances used for maintaining the space left by the loss of primary incisors, primary canines, and primary molars. These can be classified as, removable or fixed, active or passive, functional or non-functional, and unilateral or bilateral. Amongst various non-functional SMs, band and loop (B&L) SM is one of the most frequently used appliances with a high success rate. However, B&L SMs have several disadvantages too; they require impression making, tedious laboratory work, multi-visit procedure; dislodgement due to decementation of bands, cervical caries formation, slippage of the loop, and tipping of abutment teeth and often may be a source of metal allergy. Thus, to overcome these disadvantages of B&L SM, tube and loop (T&L) SMs were introduced. The design of the T&L SM is simple, quick, and easy and can also act as a space regainer. It is a single sitting procedure that does not require any laboratory work, thus, offers more advantages over the conventional B&L SMs.

¹⁻⁴Department of Pediatric Dentistry, Subharti Dental College, Meerut, Uttar Pradesh, India

⁵Department of Pediatric Dentistry, Rajasthan Dental College, Jaipur, Rajasthan, India

⁶Department of Periodontology, Uttar Pradesh University of Medical Sciences, Uttar Pradesh, India

Corresponding Author: Manisha Tyagi, Department of Pediatric Dentistry, Subharti Dental College, Meerut, Uttar Pradesh, India, Phone: +91 8279395609, e-mail: tyagimanisha208@gmail.com

How to cite this article: Tyagi M, Rana V, Srivastava N, *et al.* Comparison of the Conventional Band and Loop Space Maintainers with Modified Space Maintainers: A Split-mouth Randomized Clinical Trial. *Int J Clin Pediatr Dent* 2021;14(S-1):S60–S65.

Source of support: Nil

Conflict of interest: None

However, to overcome the disadvantages of banded SMs, attempts have been made to utilize newer materials in SMs' fabrication which omit/avoids band adaptation. Bonded SMs do not require impression making and band adaptation thus, they can be done in a single sitting and there is minimal or no discomfort to the patient. Also, in bonded B&L SMs, loop is bonded to the smooth surfaces of the teeth (buccal and palatal/lingual) with the help of composite resin. Whereas, in the bonded tube and loop (BTL) SMs, molar tubes are bonded to the buccal surface of the teeth with the help of composite resin, and a loop is inserted in them.

Due to scanty literature, there has been little comparative clinical evaluation on the comparison of banded vs bonded SMs currently available. Therefore, this study aimed to compare the efficacy of conventional B&L with conventional tube and loop (CTL), BTL and bonded loop (BL) SM in terms of gingival health, survival time and patients' and parents' satisfaction.

MATERIALS AND METHODS

A total of 15 otherwise healthy children, aged 4–9 years with grossly mutilated single molars on either side, requiring extraction or freshly extracted single molars bilaterally in the same arch or opposite arch were selected from the Outpatient Department of Pediatric and Preventive Dentistry. Ethical clearance was obtained before the study. Informed consent was obtained from parents/guardians of the children participating in the study.

Inclusion Criteria

- Clinical criteria
 - Systemically healthy children.
 - Grossly mutilated single molars on either side, requiring extraction.
 - Freshly extracted single molars bilaterally in the same arch or opposite arch.
 - Sound and healthy teeth adjacent to the extraction site.
 - No abnormal dental conditions such as crossbite, open bite, and deep bite.
- Radiographic criteria
 - Presence of succedaneous tooth bud.
 - Presence of at least 1 mm bone overlying the succedaneous tooth germ with less than one-third of the root formed.

Exclusion Criteria

- Grossly carious teeth were adjacent to the created space.
- Absence of teeth on the mesial or distal side of the teeth to be extracted.

Procedure

For every selected child, a brief history was taken followed by a clinical examination. Digital IOPA radiographs were taken for the tooth to be extracted. Impressions were made for study model preparation and space analysis. Patients were divided into three groups based on random allocation (Lottery method).

Group I—In every patient, B&L SM in one quadrant while for other quadrant BL was delivered.

Group II—In every patient, B&L SM in one quadrant while for other quadrant BTL was delivered.

Group III—In every patient, B&L SM in one quadrant while for other quadrant CTL was delivered.

Banded SMs were cemented using type I GIC (luting) and bonded SMs were bonded using composite resin. Instructions on oral hygiene and appliance maintenance were given to both children and parents.

- To brush daily with an orthodontic brush and fluoridated toothpaste twice.
- To rinse after every meal.
- To avoid consuming sticky food.

All the patients were recalled at 1st, 3rd, 6th and 9th months to compare their efficacy in terms of survival time, gingival health, and patients' and parents' satisfaction as per the following criteria:

Survival Time of SMs

Both the SMs were evaluated for de-cementation, debonding, solder breakage, loop breakage, band breakage, and/or abutment tooth fracture.

Gingival Health of the Abutment Tooth

Gingival health of both the abutment teeth was assessed according to the criteria given by Loe and Silness¹ in 1963 and the scores were recorded at each follow-up visit.

Patients' Satisfaction

Satisfaction of patients was recorded using a 5-point Likert-type scale² and the scores were recorded at each follow-up visit.

Results were statistically analyzed using independent *t*-test and Chi-square test under SPSS version 20.0 software. The 5% level of significance had been adopted for the present study: $p \leq 0.05$ = significant; $p > 0.05$ = statistically not significant.

RESULTS

The survival time of different SMs (B&L, BL, BTL, CTL) at different follow-up intervals (0, 1, 3, 6, 9 months) was observed (Table 1). On follow-up of 1-month, all the SMs in all the groups survived successfully. At a 3-month interval, 1 BL SM failed due to bond failure while all the remaining SM survived. At a 6-month interval, 1 case of BTL SM did not report while all the remaining SM survived. At the 9-month interval, 1 more BL SM failed due to bond failure while all the remaining SM survived. The difference between the survival rate at 3, 6, and 9 months was statistically non-significant ($p > 0.05$) (Fig. 1).

The comparison of gingival health of the abutment tooth using gingival index (by Loe and Silness) in all the groups at a different time interval (0, 1, 3, 6, 9 months) showed that there was mild gingivitis (0.1–1.0) in all the cases till 1st month. However, the group with BL exhibited moderate (1.1–2.0) gingivitis starting from 3rd month onward (Table 2 and Fig. 2).

Intergroup comparison of parents'/patients' acceptance (Table 3) for all the groups at a different time interval (0, 1, 3, 6, 9 months) showed that for the total 9-month follow-up, the mean of patients'/parents' perception was found to be statistically significant ($p < 0.05$) between group I, II, and III (Fig. 3).

DISCUSSION

The B&L SMs are the most common, however, to overcome their disadvantages, T&L SMs were introduced. The T&L is simple, quick, easy, and can also act as a space regainer. It is a single sitting procedure that does not require any laboratory work, thus, offers more advantages over the conventional B&L SMs. Another advantage of this SM is that the loop can easily be rotated up for routine cleaning of the area, adjusted/activated by coiling or uncoiling the helix, and can be removed if required, without disturbing the bands.³

But because of the various disadvantages associated with the banded type of SMs, attempts have been made to utilize newer materials in SM's fabrication which omit/avoids band adaptation.

Table 1: Group comparison of survival time at a different follow-up interval

Group	Survival time of space maintainer	Follow-up					
		0 month	1 month	3 months	6 months	9 months	
Group I	B&L	Survived	5	5	5	5	5
		Failed	0	0	0	0	0
	BL	Survived	5	5	4	4	3
		Failed	0	0	1	1	2
	<i>p</i> value	–	–	0.292 (NS)	0.292 (NS)	0.114 (NS)	
Group II	B&L	Survived	5	5	5	5	5
		Failed	0	0	0	0	0
	BTL	Survived	5	5	5	4	4
		Failed	0	0	0	1	1
	<i>p</i> value	–	–	–	0.292 (NS)	0.292 (NS)	
Group III	B&L	Survived	5	5	5	5	5
		Failed	0	0	0	0	0
	CTL	Survived	5	5	5	5	5
		Failed	0	0	0	0	0
	<i>p</i> value	–	–	–	–	–	

NS, non-significant; *(*p* < 0.05): significant

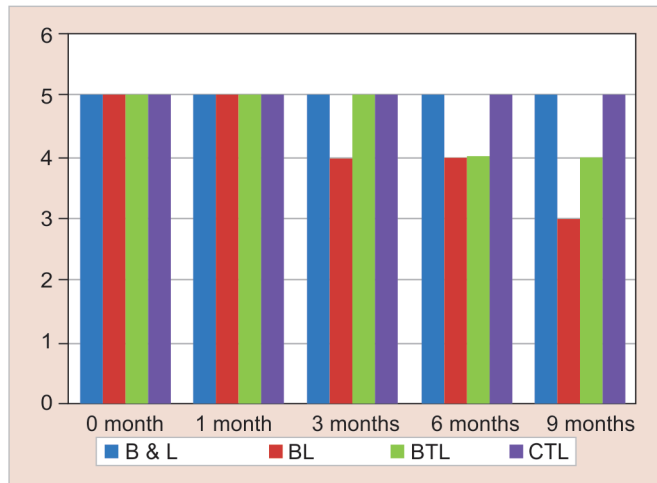


Fig. 1: Group comparison of survival time at a different follow-up intervals

Thus, bonded SMs were introduced which do not require impression making and band adaptation and can be done in a single sitting with minimal or no discomfort to the patient.

In the present study, in group I and group II, the survival time was 100% (*n* = 5) for B&L SMs whereas 60% (*n* = 3) and 80% (*n* = 4) for BL and BTL SMs, respectively, till 9-month follow-up. The reason for failure in bonded SM was because of debonding of the composite that could be attributed to inadequate moisture control, the morphology of the tooth and chemical composition of the material used to bond the appliance, the arch in which SMs were given, and the abutment tooth (primary or permanent tooth) being bonded.⁴

Also, the bond strength of primary tooth enamel is considerably lower than the permanent tooth enamel due to the presence of prismless zones in the enamel of primary teeth, which tend to have an adverse effect on the bond strength thereby, affecting resin retention.⁵ Occlusal trauma might be also one of the causes in

cases of newly erupted teeth where the area available for bonding is inadequate.⁶⁻⁹

In the present study, oral health was evaluated in terms of gingival health using the gingival index which is a simple, accurate method in epidemiological and clinical research.¹⁰⁻¹³ In group I, for a follow-up of 1st month, there was mild gingivitis (0.1–1.0) in both the cases. However, the group with BL exhibited moderate (1.1–2.0) gingivitis starting from the 3rd month onward whereas the group with BL remained mild. Thus, among both the SMs (B&L, BL), BL SMs had good gingival health till the 9-month follow-up. The reason for moderate gingivitis could be attributed to some unpolished margins that might have been left in the bands after festooning and trimming and these unpolished margins had become a source for bacteria to harbor and grow for a 9-month long interval. Thus, causing moderate gingivitis.¹⁴⁻¹⁶

In group II, B&L exhibited moderate gingivitis (mean–1.20) starting from 3 months onward up to 9 months whereas the group with BTL exhibited mild gingivitis (mean–0.40) at 3- and 9-month follow-up. Therefore, it can be stated that among both the SMs (B&L, BTL), BTL SMs exhibited good gingival health till the 9-month follow-up.

Mild gingivitis present in the bonded SMs could be attributed to the fact that composite is not “gingiva friendly” and its unpolished surfaces attract plaque accumulation.¹¹

In group III, B&L exhibited moderate gingivitis (mean–1.20) starting from the 3rd month onward whereas the group with CTL remained mild (mean–0.80). Thus, when B&L and CTL were compared, CTL proved to be superior in terms of gingival health. As CTL had a more hygienic design as compared to BL, because of the presence of a freely movable loop in CTL.

Though oral hygiene instructions were given to all the patients, still, the area around the appliance was not clean, as a result, gingivitis was seen. The findings of the present study emphasize the importance of maintaining good oral hygiene and plaque control during SM treatment. According to Subramaniam et al. bonded SMs are likely to permit better oral hygiene maintenance, because of no injury to the gingival tissue.⁹



Table 2: Group comparison of gingival health of abutment tooth at a different follow-up intervals

Group	Follow-up	N	Mean	Std. deviation	Mean difference	p value	
Group I B&L vs BL	B&L	0 month	5	0.40	0.548	0.200	0.545 (NS)
	BL		5	0.20	0.447		
	B&L	1 month	5	0.60	0.548	0.400	0.242 (NS)
	BL		5	0.20	0.447		
	B&L	3 months	5	1.20	0.447	0.800	0.035*
	BL		5	0.40	0.548		
	B&L	6 months	5	1.40	0.548	1.000	0.02*
	BL		5	0.40	0.548		
	B&L	9 months	5	1.60	0.548	1.200	0.009*
BL		5	0.40	0.548			
Group II B&L vs BTL	B&L	0 month	5	0.40	0.548	0.200	0.545 (NS)
	BTL		5	0.20	0.447		
	B&L	1 month	5	0.60	0.548	0.400	0.242 (NS)
	BTL		5	0.20	0.447		
	B&L	3 months	5	1.20	0.837	0.800	0.111 (NS)
	BTL		5	0.40	0.548		
	B&L	6 months	5	1.40	0.548	1.000	0.02*
	BTL		5	0.40	0.548		
	B&L	9 months	5	1.60	0.548	1.000	0.02*
BTL		5	0.60	0.548			
Group III B&L vs CTL	B&L	0 month	5	0.40	0.548	0.200	0.545 (NS)
	CTL		5	0.20	0.447		
	B&L	1 month	5	0.60	0.548	0.200	0.58 (NS)
	CTL		5	0.40	0.548		
	B&L	3 months	5	1.20	0.837	0.400	0.373 (NS)
	CTL		5	0.80	0.447		
	B&L	6 months	5	1.40	0.894	0.600	0.217 (NS)
	CTL		5	0.80	0.447		
	B&L	9 months	5	1.60	0.548	0.600	0.04*
CTL		5	1.00	0.000			

NS, non-significant; *($p < 0.05$): significant

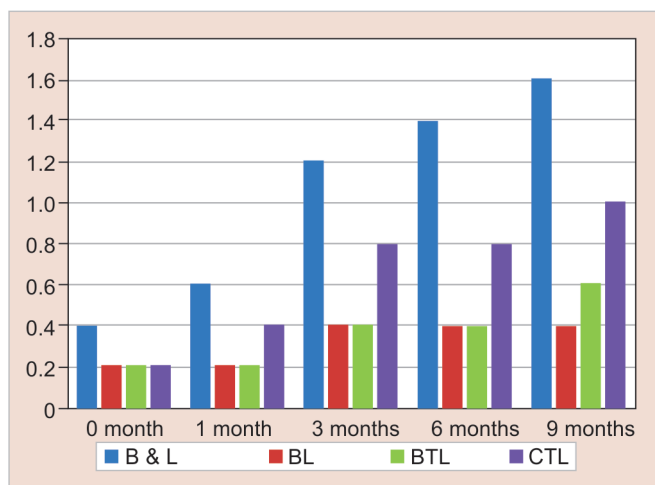


Fig. 2: Group comparison of gingival health of abutment tooth at a different follow-up intervals

In the present study, patients' and parents' satisfaction was assessed in the groups using the Likert 5-point scale because of its adequate reliability and validity.²

In group I and II, patients' and parents' satisfaction were more toward bonded SMs. A highly significant difference was found between B&L-BL and B&L-BTL in terms of patients' acceptance. The reason could be attributed to the fact that there was no Impression making and band adaptation and the whole procedure could be completed in a single sitting which caused minimal or little discomfort to the patient.

In group III, for patients' and parents' satisfaction, when B&L SM was compared with CTL SM, the mean of patient's and parents' satisfaction at 0th and 1st month were found to be statistically non-significant. However, the mean of patients'/parents' perception at 3rd, 6th, and 9th months were statistically significant ($p < 0.05$). Thus, suggesting patients' and parents' satisfaction was significantly higher in the CTL group when compared with the BL group as it is a single visit procedure, economical, no requirement of impression, and a freely movable loop which attributed to good hygiene.

Table 3: Group comparison of patients' acceptance at a different follow-up intervals

Groups		Follow-up	N	Mean	Std. deviation	Mean difference	p value
Group I B&L vs BL	B&L	0 month	5	3.00	1.000	-1.400	0.025*
	BL		5	4.40	0.548		
	B&L	1 month	5	3.20	0.837	-1.400	0.014*
	BL		5	4.60	0.548		
	B&L	3 months	5	3.20	1.304	-1.400	0.058 (NS)
	BL		5	4.60	0.548		
	B&L	6 months	5	3.20	0.837	-1.600	0.005*
	BL		5	4.80	0.447		
	B&L	9 months	5	3.40	1.140	-1.600	0.014*
BL		5	5.00	0.000			
Group II B&L vs BTL	B&L	0 month	5	3.00	0.707	-1.400	0.025*
	BTL		5	4.40	0.894		
	B&L	1 month	5	3.20	0.837	-1.200	0.06 (NS)
	BTL		5	4.40	0.894		
	B&L	3 months	5	3.20	0.837	-1.200	0.06 (NS)
	BTL		5	4.40	0.894		
	B&L	6 months	5	3.20	0.837	-1.600	0.005*
	BTL		5	4.80	0.447		
	B&L	9 months	5	3.40	0.894	-1.400	0.014*
BTL		5	4.80	0.447			
Group III B&L vs CTL	B&L	0 month	5	3.00	1.225	-1.000	0.153 (NS)
	CTL		5	4.00	0.707		
	B&L	1 month	5	3.20	0.837	-0.800	0.141 (NS)
	CTL		5	4.00	0.707		
	B&L	3 months	5	3.20	0.447	-1	0.046*
	CTL		5	4.20	0.837		
	B&L	6 months	5	3.20	0.447	-1.200	0.005*
	CTL		5	4.40	0.548		
	B&L	9 months	5	3.40	0.548	-1.000	0.02*
CTL		5	4.40	0.548			

NS: non-significant; *($p < 0.05$): significant

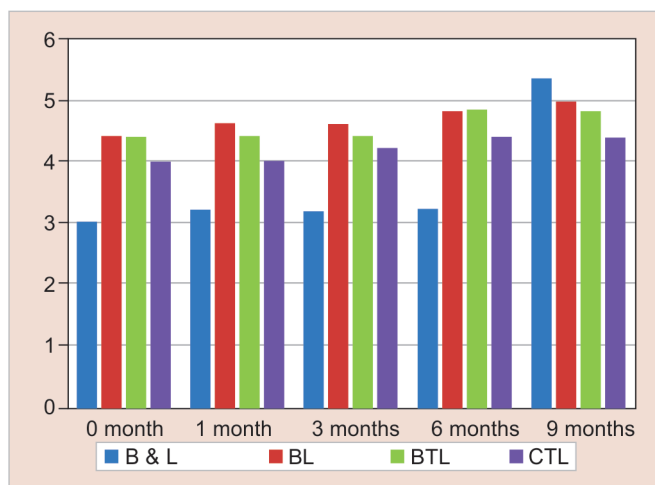


Fig. 3: Group comparison of patients' acceptance at a different follow-up intervals

According to Deshpande et al., the appropriate design and fabrication, meticulous oral hygiene maintenance, and regular follow-ups would certainly make bonded SMs a viable alternative to the conventional banded appliances.¹⁰

CONCLUSION

Based on the results of the study, the following conclusions were drawn:

- All the SMs proved to be clinically successful in terms of survival time, gingival health, and patients' and parents' satisfaction.
- 100% of the CTL and B&L survived till 9 months. The success rate of the BTL SMs was 80% whereas only 60% of the bonded B&L SMs survived till the end of the study.
- Though, none of the SMs were found to be absolutely gingival friendly, CTL SM showed the best results in terms of gingival health. Whereas, B&L SM showed the worst results.
- Both patients and parents were totally satisfied with the bonded (BTL and BL) SMs.

- Upon evaluating all the parameters, the efficacy of different types of SMs can be summarized as CTL > B&L > BTL > BL.

However, further studies are needed to be conducted on larger sample size and with long-term follow-up to evaluate the efficacy of these SMs in terms of survival time, gingival health, and patients' and parent's satisfaction.

CLINICAL SIGNIFICANCE

To find a better alternative to conventional SMs which requires less patients' compliance.

REFERENCES

1. Löe H. The gingival index, the plaque index and the retention index systems. *J Periodontol* 1967;38(6):610–616. DOI: 10.1902/jop.1967.38.6.610.
2. Hojat M, Louis DZ, Maxwell K, et al. A brief instrument to measure patients' overall satisfaction with primary care physicians. *Fam Med* 2011;43(6):412–417.
3. Srivastava N, Grover J, Panthri P. Space maintenance with an Innovative "Tube and Loop" space maintainer (Nikhil Appliance). *Int J Clin Pediatr Dent* 2016;9(1):86–89. DOI: 10.5005/jp-journals-10005-1340.
4. Sakaguchi RL. Review of the current status and challenges for dental posterior restorative composites: clinical, chemistry, and physical behavior considerations. Summary of discussion from the Portland composites symposium (POCOS) June 17–19, 2004, Oregon Health and Science University, Portland, Oregon. *Dent Mater* 2005;21(1):3–6. DOI: 10.1016/j.dental.2004.10.008.
5. Bhasin AS. Simplified bonded space maintainer—a case report. *J Indian Dent Assoc* 2011;5(1):29.
6. Swartz ML, Philips RW, Clark HE. Long-term F release from glass ionomer cements. *J Dent Res* 1984;63(2):158–160. DOI: 10.1177/00220345840630021301.
7. Millett DT, McCabe JF, Bennett TG, et al. The effect of sandblasting on the retention of first molar orthodontic bands cemented with glass ionomer cement. *Br J Orthod* 1995;22(2):161–169. DOI: 10.1179/bjo.22.2.161.
8. Swaine TJ, Wright GZ. Direct bonding applied to space maintenance. *J Dent Child* 1976;43(6):401–405.
9. Subramaniam P, Babu G, Sunny R. Glass fiber-reinforced composite resin as a space maintainer: a clinical study. *J Indian Soc Pedod Prev Dent* 2008;26(3):98–103. DOI: 10.4103/0970-4388.43192.
10. Deshpande SS, Bendgude VD, Kokkali VV. Survival of bonded space maintainers: a systematic review. *Int J Clin Pediatr Dent* 2018;11(5):440–445. DOI: 10.5005/jp-journals-10005-1554.
11. Peter S. *Essentials of preventive and community dentistry*. 4th ed., Arya Medi Publishing House Pvt Ltd; 2010. pp. 492–493.
12. Qudeimat MA, Fayle SA. The longevity of space maintainers: a retrospective study. *Pediatr Dent* 1998;20(4):267–272.
13. McDonald RE, Avery DR. *Dentistry for the child and adolescent*. 7th ed., 2001. pp. 677–741.
14. Tunison W, Flores-Mir C, ElBadrawy H, et al. Dental arch space changes following premature loss of primary first molars: a systematic review. *Pediatr Dent* 2008;30(4):297–302.
15. Tanić T, Blazej Z, Radojicic J. The effects of early loss of primary lateral teeth. *FU Med Biol* 2008;15(2):68–73.
16. Ghafari J. Early treatment of dental arch problems - space maintenance, space gaining. *Quintessence Int* 1986;17(7):423–432.