

CASE REPORT

Management of Asymmetric Mandibular Retrognathia with Differential Loading Technique: A Case Report

Ajit V Parihar¹, Kavin Prasanth Angamuthu², Rojalin Sahoo³, Shivam Verma⁴

ABSTRACT

Class II malocclusion cases possess a constant challenge to orthodontists since time immemorial. Mandibular retrusion is the most common feature of class II malocclusion, rather than maxillary prognathism. Association of class II with asymmetry, a condition called asymmetric mandibular retrognathia (AMR), gives a tougher challenge to orthodontists for management. The following case presents effective management of AMR using differential loading technique. A young boy aged 12 years presented with mandibular retrognathia associated with facial asymmetry. He was treated with a differential force loading technique using a fixed functional appliance.

Results: Improved facial profile with increased mandibular length achieved. A significant reduction in facial asymmetry was also appreciable.

Conclusion: Differential force loading technique using fixed functional appliance while being least troublesome for the patient may prove beneficial to harness excellent and satisfactory results with minimal efforts in such cases of mandibular retrusion with facial asymmetries and also decrease the need for surgical correction.

Keywords: Asymmetry, Congenital torticollis, Differential loading, Fixed functional appliance, Mandibular retrognathia, Plagiocephaly, PowerScope 2.

International Journal of Clinical Pediatric Dentistry (2021): 10.5005/jp-journals-10005-1969

INTRODUCTION

Orthodontists face class II malocclusion as a substantial and frequent challenge during their practice.¹ Class II malocclusion can be either a dental class II or a skeletal class II or may include both components.² According to McNamara,³ mandibular retrusion, rather than maxillary prognathism, is the most commonly associated feature of class II malocclusion. The degree of severity of the problem and the age of the patient at which he/she reports to seek treatment primarily govern the management of class II malocclusion. Management of such malocclusion creates a major challenge for orthodontists in terms of treatment planning and successful management.

The complexity of the case increases if such malocclusions are associated with some congenital deformities that hamper the facial symmetry and growth of the individuals. Congenital torticollis is one such condition disturbing the pleasing symmetry of a face.

Prenatally acquired congenital muscular torticollis (CMT) is the most common type of torticollis which is due to the asymmetric length and/or strength of the sternocleidomastoid (SCM) muscles on each side of the neck that has been replaced by dense fibrous tissue, its association with positional plagiocephaly is also very common.⁴ Chronologically, asymmetrical mandibular growth is the first indication of CMT, followed by occlusal abnormalities, lastly orbital, and maxillary at an older age. The craniofacial appearance and the stigma attached along with CMT have been identified as one of the prime concerns of the parents.⁴

Amin et al.⁵ studied children with such deformities and concluded that they were affected not only functionally but also psychologically due to surrounding peer pressure. Treatment in such patients should be carried out as early as possible because of the growth that is present at a younger age.

The recommended treatment of skeletal jaw asymmetry is usually surgical at the end of growth, although in cases with

^{1,3,4}Department of Orthodontics and Dentofacial Orthopedics, Unit of Orthodontics, Faculty of Dental Sciences, Institute of Medical Sciences, Banaras Hindu University, Varanasi, Uttar Pradesh, India

²Department of Orthodontics and Dentofacial Orthopedics, Unit of Orthodontics, Ramakrishna Dental College, Coimbatore, Tamil Nadu, India

Corresponding Author: Rojalin Sahoo, Department of Orthodontics and Dentofacial Orthopedics, Unit of Orthodontics, Faculty of Dental Sciences, Institute of Medical Sciences, Banaras Hindu University, Varanasi, Uttar Pradesh, India, Phone: +91 7607510098, e-mail: rojalinsahoo76457@gmail.com

How to cite this article: Parihar AV, Angamuthu KP, Sahoo R, et al. Management of Asymmetric Mandibular Retrognathia with Differential Loading Technique: A Case Report. *Int J Clin Pediatr Dent* 2021;14(S-1):S104-S110.

Source of support: Nil

Conflict of interest: None

minor asymmetry early intervention is recommended. The early intervention of minor/moderate asymmetry can be done with hybrid functional appliances by differential loading of the force to stimulate growth more on the affected side.⁶ These appliances have to be customized and tailor-made for exploiting the natural processes of growth and development. Achieving an appreciable balance using a myofunctional appliance can considerably reduce facial deformity which will reduce the complexity of orthognathic surgery performed at a later age.⁷

The following case presents effective management of skeletal class II discrepancy along with facial asymmetry, a condition called asymmetric mandibular retrognathia (AMR) in a patient with congenital torticollis history, using differential loading of forces.

CASE DESCRIPTION

A 12-year-old male reported with chief complaint of forwardly placed upper front teeth and the inability to close the lips.

Extraoral Examination (Fig. 1)

On an extraoral examination, the patient had facial fullness on the right side of the face and flatness on the left side of the face. He was having plagiocephaly (flat head) with a mesoprosopic facial form, convex facial profile, posterior divergence, and a hypotonic lower lip with a lip trap. The patient had a deep mentolabial sulcus, hyperactive mentalis, average clinical FMA, and positive visual treatment objective on the advancement of the mandible. The ears appeared asymmetrical along with a smaller eye and a flattened jawline on the left side. Also, depression on the left side of the neck was noticed.

Since the patient was found with fullness on the right side of the face and flatness on the left side, the patient's parents were asked for his birth history regarding any trauma/injury during birth. As reported by the patient's mother, the patient was born with a tilted head toward the left side (torticollis) and underwent some home remedies that caused a slight improvement. The past medical records suggest that the patient was a diagnosed case of congenital torticollis.

Intraoral Examination (Fig. 2)

Intraorally, the patient presented in late mixed dentition with class II division 1 incisor relationship, spacing in upper anteriors, increased overjet of 12 mm, and deep bite of 10 mm. The permanent canines and premolars had not erupted into the oral cavity so far. The maxillary incisors were proclined and the maxillary arch was mildly constricted in the anterior region. The molar relation was full cusp

class II on both right and left sides. The curve of Spee was 7 mm on the right and 5 mm on the left side. A dental midline shift of 2 mm toward the lower left side was also appreciated.

Cephalometric Analysis

The lateral cephalometric readings (Tables 1 and 2) showed a skeletal class II pattern with ANB of 8°, Wits AO 7 mm ahead of BO, more sensitive and specific angles for assessing sagittal skeletal analysis like Beta, Yen, and Mu angles were found to be 21°, 110°, and 8°, respectively (all indicating a skeletal class II pattern), retrognathic mandibular length with SNB 73°, an average growth pattern with downs Y-axis of 58°, FMA of 23°, SN-Go-Gn of 30°, a facial axis of 86°, Jaraback ratio of 65%. Dentoalveolar analysis (Table 3) inferred proclined upper anteriors (U1-SN of 117°, U1-NA 32°) and retroclined lower anteriors (L1-NB 21°, 3 mm, IMPA 88°). Soft tissue analysis (Table 3) indicated an obtuse nasolabial angle of 93° and protruded upper and retruded lower lip. Cephalometric radiograph (Fig. 3) revealed CVMI stage 3 (considered suitable to give functional appliance). OPG (Fig. 4) revealed permanent canines and premolars were in the erupting stage.

The posteroanterior cephalometric radiograph (Table 4 and Fig. 5) was analyzed using Grummons and Ricketts analysis that revealed facial asymmetry and the right side was found larger dimensionally than the left side of the face.

Problem List

The overall problems of the patient have been summed up in Table 5.

Treatment Objective

To achieve esthetically acceptable, symmetrical profile and functionally optimal occlusion with stability, achieve functional

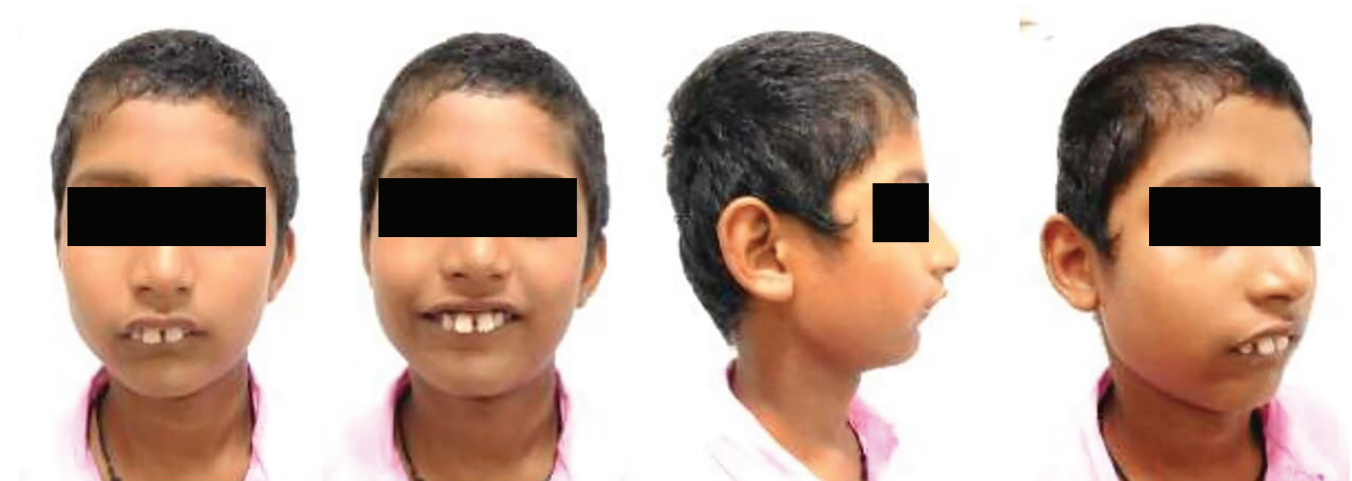

Fig. 1: Pretreatment extraoral photographs

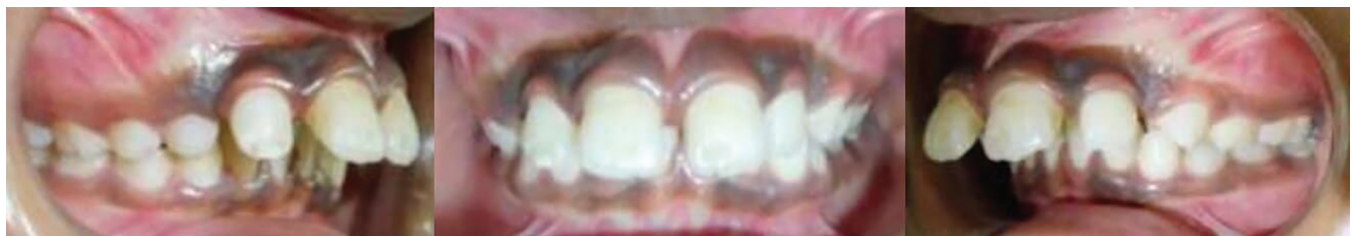

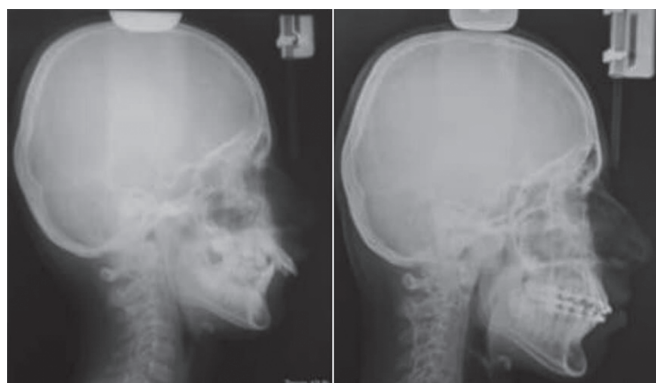Fig. 2: Pretreatment intraoral photographs

Table 1: Skeletal changes in sagittal plane at pretreatment and posttreatment

Parameters	Pretreatment	Posttreatment
SNA	81	80
SNB	73	76
ANB	8	5
SN-Pog	75	78
WITS	AO 7 mm ahead of BO	AO 2 mm ahead of BO
Beta angle	21	26
Yen angle	110	114
Mu angle	8	16
Skeletal change in maxillary and mandibular length		
Maxillary (Schwarz)	42	48
Mandibular (Schwarz)	53	57
Maxillary (McNamara)	70	68
Mandibular (McNamara)	83	87
Ramus length	43	45

Table 2: Skeletal changes in vertical plane at pretreatment and posttreatment

Parameters	Pretreatment	Posttreatment
SN-GoGn	30	35
Y-axis	58	62
FMA	23	26
Lower gonial angle	80	80
Sum of posterior angles	391	398

**Fig. 3:** Pretreatment and posttreatment lateral cephalogram

correction of skeletal class II malocclusion, to correct dental midline, to attain class I molar relation and class I canine relation on both sides, achieve proper inclination of upper and lower anteriors with normal overjet and overbite and an esthetically pleasing soft tissue profile without extracting teeth.

Probable Treatment Plans

In treatment options, we had the option of either doing skeletal discrepancy correction by using a removable, fixed functional appliance, or hybrid functional appliance or opting for orthodontic camouflage with extraction in the upper arch. The patient was explained about all the treatment options. But finally, taking the age, growth, and compliance into consideration and the non-inclination of the patient's parents toward extraction, a non-extraction approach was planned using a contemporary fixed orthodontic appliance. After leveling and aligning, a fixed functional appliance was chosen to advance the mandible to attain a class I relationship and to stimulate the growth of the mandible by differential loading followed by finishing and detailing.

Treatment Sequencing

Full fixed pre-adjusted edgewise appliance MBT 0.022" prescription was placed on all the erupted permanent teeth to level and align both arches. As the unerupted permanent teeth started erupting into the oral cavity, they were also bonded progressively and were properly aligned and leveled. After achieving the leveling and alignment within 6 months (Fig. 6) and transpalatal arch placed in the maxillary arch for reinforcement of anchorage. 0.019" × 0.025" stainless steel archwires were inserted after the figure of eight ligation from the first molar to the first molar in both arches and 20° of labial

Table 3: Cephalometric assessment of dental and soft tissue pretreatment and posttreatment

Parameters	Pretreatment	Posttreatment
U1-NA	32	22
U1-NA	6 mm	3 mm
U1-SN	113	98
L1-NB	21	28
L1-NB	3.5 mm	5 mm
IMPA	89	97
Interincisal angle	119	120
Soft tissue		
Nasolabial angle	93°	130
E line-upper lip	1 mm ahead	1 mm behind
E line-lower lip	3.5 mm behind	2 mm ahead

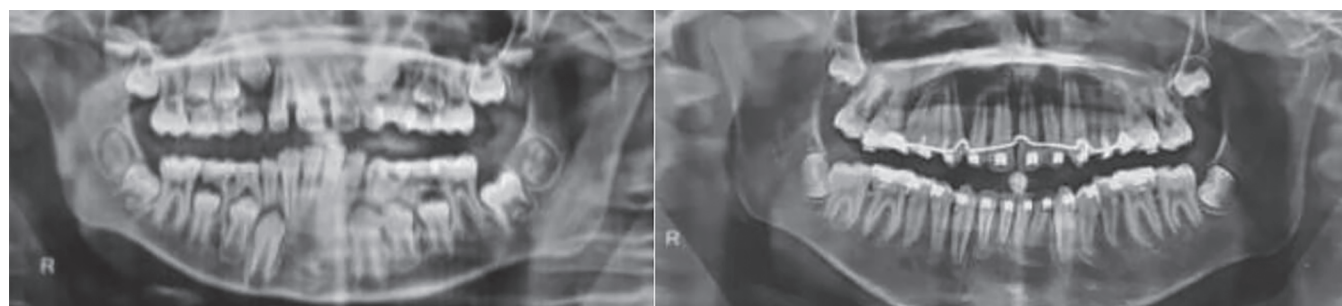**Fig. 4:** Pretreatment and posttreatment OPG

Table 4: Posteroanterior cephalometric readings (Ricketts and Grummons analysis)

<i>Ricketts analysis</i>	<i>Pretreatment</i>		<i>Posttreatment</i>		
Maxillomandibular width	R 13 mm	L 12 mm	R 13 mm	L 13 mm	
Maxillomandibular midline	2° deviation with respect to MSP		1° deviation with respect to MSP		
Denture jaw midline	Lower midline shifted 1 mm to ANS-Me		No shift in midline to ANS-Me		
Jaw to cranium relation	R 15°	L 13°	R 15°	L 14°	
<i>Grummons analysis</i>	<i>Pretreatment</i>		<i>Posttreatment</i>		
Mandibular morphology analysis	Co-Ag linear	R 49	L 47	R 51	L 50
	Ag-Me linear	42	39	44	43
	Co-Me linear	76	75	83	83
	Angle Co-Ag-Me	118	117	120	120
Maxillomandibular comparison of asymmetry	The constructed lines drawn perpendicular to MSR from Ag and J bilaterally, did not form triangles named J-Cg-J and Ag-Cg-Ag suggesting the absence of symmetry		The constructed lines drawn perpendicular to MSR from Ag and J bilaterally, form triangles named J-Cg-J and Ag-Cg-Ag suggesting symmetry		
Linear asymmetry assessment	Co-MSR	R 42	L 39	R 42	L 41
	Nc-MSR	12	10	12	12
	J-MSR	27	24	28	27
	Ag-MSR	39	35	38	36

root torque was given in lower anteriors taking into account the slope of 10° with a 0.019" × 0.025" stainless steel archwire in 0.022" slot. A fixed functional class II corrector appliance, the PowerScope 2 was placed (Fig. 7) and differential loading of forces was done with more activation on the left side (flat side) by adding extra crimps to correct the lower dental midline deviation and improve the mandibular retrognathism and achieve class I relationship on both sides. Frequent debonding of the lower canine bracket/upper buccal tube was not confronted during the treatment with this appliance because the PowerScope 2 was anchored onto the orthodontic wire. After 6 months, the PowerScope 2 was removed (Fig. 8). Retention of skeletal class II correction was accomplished with a fixed upper anterior inclined plane and the patient was also advised to wear class II elastics. Finishing was accomplished with 0.019" × 0.025" TMA archwires and lighter 0.016" stainless steel with vertical elastics for final settling. Final stage OPG, lateral cephalograms, and photographs were taken. Pretreatment and posttreatment cephalometric readings (Tables 1 to 4) were compared and superimpositions (Fig. 9) were made. Within a total period of around 28 months (Table 6); skeletal and dental class I relationships had been attained, after which the fixed appliances were removed.

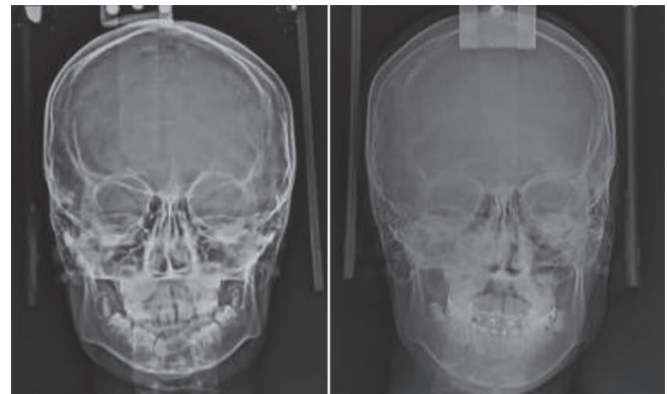

Fig. 5: Pretreatment and posttreatment PA view

Table 5: Problem list

	<i>Maxilla</i>	<i>Mandible</i>	<i>Maxillomandibular</i>
Skeletal			
Transverse		Asymmetrical readings of R and L sides of mandibular morphology-Co-Ag linear R 49 mm, L 47 mm; Ag-Me R 42 mm, L 39 mm; Co-Me linear R 76 mm, L 75 mm; Linear asymmetry assessment also indicates asymmetry between R and L sides	Absence of symmetry between right and left sides-Maxillomandibular width R 13 mm, L 12 mm; Maxillomandibular midline is 2° deviated from MSP; Jaw to cranium relation R 15°, L 13°
Vertical			Average growth pattern, SNGoGn 30°, Y-axis 58°, FMA 23°
Sagittal		Deficient mandible SNB 73°, SN-Pog 75°	Class II pattern, ANB 8°, Wits 7 mm ahead of BO, beta angle 21°, Yen angle 110°, Mu angle 8°
Dental			
Transverse		Lower midline shift of 1 mm to ANS-Me	
Vertical		Curve of Spee 7 mm on right and 5 mm on left side	Overbite of 10 mm (deep bite)
Sagittal	Proclined upper anteriors, spacing in upper anteriors	Retroclined lower anteriors	Class II molar relations on both sides, class II division 1 incisor relationship, increased overjet of 12 mm and a dental midline shift of 2 mm toward lower left side
Soft tissue	Protruded upper lip	Retruded lower lip, deep mentolabial sulcus	Obtuse nasolabial angle of 93°

Treatment Results Achieved

Improved facial profile with increased mandibular length achieved (Fig. 10). Dentally, proper inclination of upper and lower incisors with adequate overjet and overbite achieved. Class I molar and class I canine relation achieved on both sides. Increased lower anterior facial height was found. Improved facial balance with a significant reduction in asymmetry and soft tissue profile attained.

Retention Protocol

Wrap around retainer in the maxillary arch with a guided inclined plane and fixed lingual retainer in the mandibular arch. Six-month recall appointment for retention check.

DISCUSSION

Class II malocclusion is considered to present a constant challenge to orthodontists among all malocclusions.⁸ Mandibular retrusion, most commonly associated with class II malocclusions, is most commonly managed by delivering orthopedic force with functional

Table 6: Treatment chronology

<i>Leveling and alignment</i>	<i>Pre-functional</i>	<i>Functional</i>	<i>Settling</i>	<i>Finishing and detailing</i>
6 months	2 months	10 months	5 months	4 months

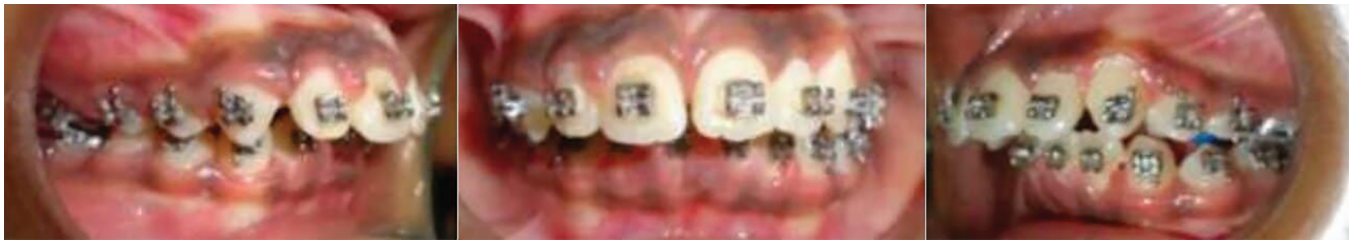

Fig. 6: Intraoral photographs after alignment and leveling

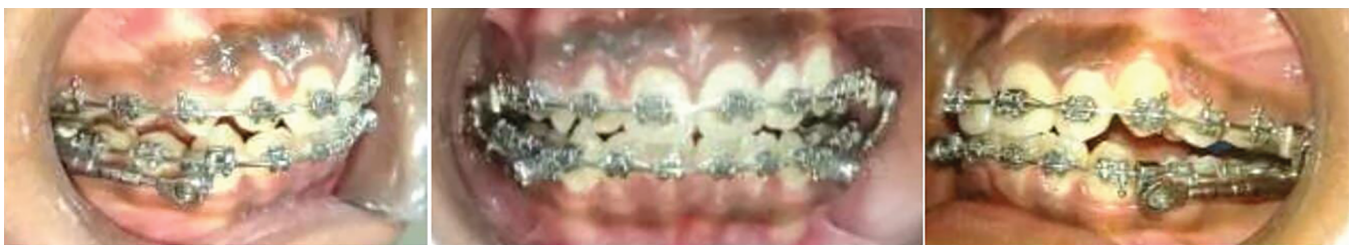


Fig. 7: Intraoral photographs with PowerScope application

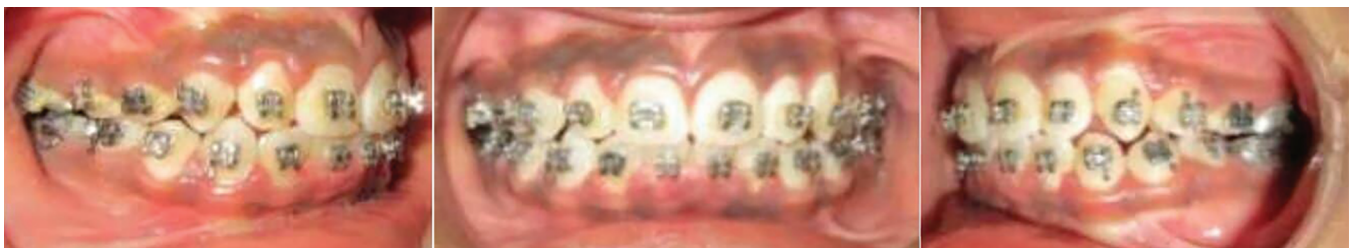

Fig. 8: Intraoral photographs after mandibular advancement and PowerScope removal

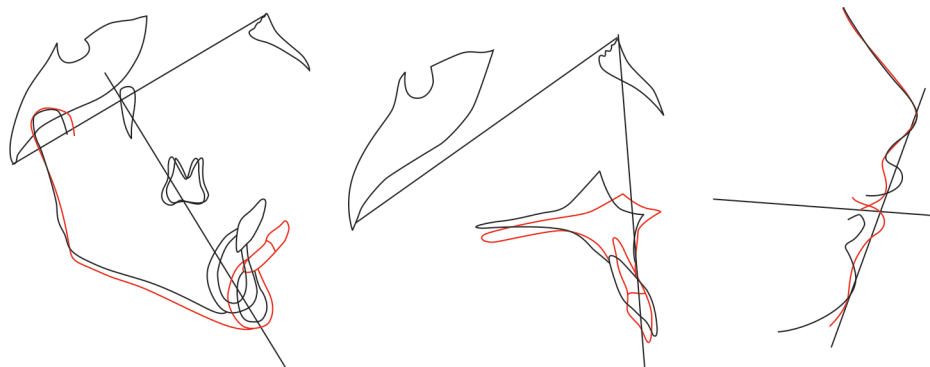

Fig. 9: Hard tissue and soft tissue superimposition

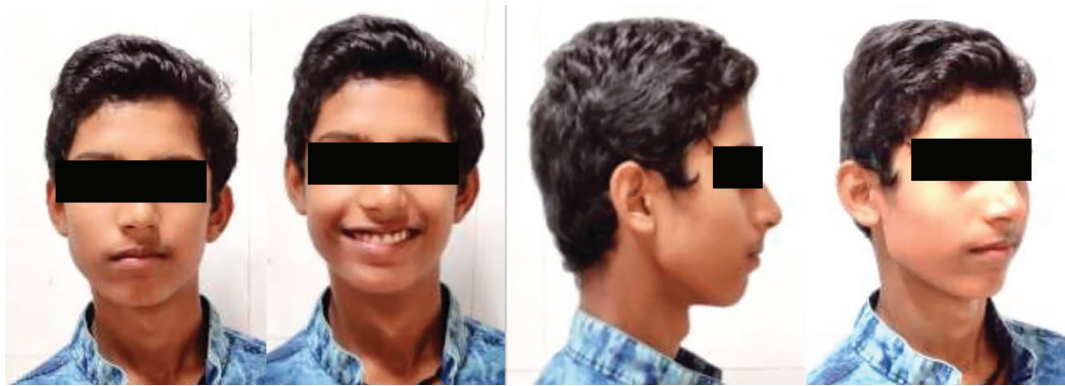

Fig. 10: Posttreatment extraoral photographs

appliances directed at the condyle of the mandible facilitating remodeling changes at the mandibular condyle as well as glenoid fossa, resulting in a repositioning of the condyle in the glenoid fossa and also may cause mandibular autorotation.⁹ There exist two types of appliances to facilitate the same—removable or fixed appliances.

In patients before adolescent growth spurt, i.e., during periods of active growth, removable functional appliances may be given.⁸ In contrast, patients reporting after the pubertal growth spurt or during later stages of puberty, i.e., deceleration stages of growth, fixed functional appliances would be a better treatment choice to make prudent use of the residual growth left in neglected and non-compliant post-adolescent patients. Fixed functional systems offer absolute advantages over removable systems. Also, their compact, concise, and small size design permitting better adaptation to functions such as mastication, swallowing, speech, and breathing, and hence better patient tolerance.

Since at CVMI stages 3 and 4 (circumpubertal), the maximum craniofacial growth velocity is anticipated and peak mandibular growth velocity occurs in this stage leading to the greatest amount of mandibular growth.¹⁰ Had the patient discussed in this case, not been treated before the pubertal growth spurt, asymmetry of the face would have increased with the increasing age of the patient.

Asymmetric mandibular retrognathia associated with facial asymmetry demands a modified treatment approach unlike the one only presented with mandibular retrusion. Treatment for CMT with mandibular retrognathia varies with age and the severity of the presentation. Early infants are treated with effective neck stretches to achieve an increased range of motion of the restricted neck. Clarren et al.,¹¹ one of the pioneers in this field, suggested the use of orthotic helmets for the resolution of plagiocephaly and improvements in skull shape. Botulinum toxin (Botox) has been recommended to enhance the effectiveness of stretching on the side of the contracture and allow the strengthening of overstretched and weakened muscles on the opposite side of the neck.⁴ In older children and adults with uncorrected CMT, craniofacial deformities may persist, resulting in obvious facial asymmetry.

Though the hybrid appliance works satisfactorily on a patient who was affected by asymmetry, patient cooperation is mandatory in such cases. In children with obvious growth potential, appliances with differential force delivery systems work satisfactorily without depending too much on patient compliance. The principle behind this hybrid appliance was to stop the growth on the fullness side as much as possible and to allow growth on the flatness side leading to partial correction of the asymmetry. After treating the case with an approach of differential force loading using a class II corrector,

cephalometric readings exhibit an appreciable improvement in skeletal, dental, and soft tissue parameters (Tables 1 to 3). The measurements of posttreatment cephalometric radiograph demonstrated favorable sagittal skeletal changes. 1° reduction in SNA angle (80°) was observed posttreatment. A mandibular advancement was clearly appreciated as SNB angle increased from 73° to 76° and a 3° reduction in ANB angle and 5 mm advancement of BO in Wits appraisal was noticed. Beta angle increased by 5° (from 21° to 26°), Yen angle increased by 4° (from 110° to 114°) while My angle increased by 8° (from 8 to 16). An increase in mandibular length was also discernible after skeletal correction (Table 1). A mild increase in lower facial height within normal limits was noticed at the end of the treatment. The maxillary incisors angulation became upright as U1-NA reduced from 32° to 22° whereas mandibular incisors proclined by 1.5 mm linear and 7° angular. IMPA could be extended up to 100° as per Indian norms.¹² Here, we ended up with an IMPA of 97°. This slight mandibular incisor proclination at the end of the treatment could be attributed to force concentration in the lower anterior segment during treatment with a fixed functional appliance. However, the use of MBT brackets (−6° torque in the lower incisor) with additional torque incorporated, consolidation of the molar to molar in both arches, cinching off the lower archwire, and use of pre-torqued wire before insertion of the PowerScope 2 has proved beneficial to counteract the proclining effect on mandibular incisors. An approximately normal interincisal angle of 120° was achieved. A considerable improvement in soft tissue was appreciated with an increased tendency toward an orthognathic pleasant profile. The lower lip relation to E line improved remarkably from −3.5 to +2 mm. A marked improvement in Upper lip to E line distance along with nasolabial angle was also discernible. Apart from the skeletal class II correction, significant improvement in the facial asymmetry could also be appreciated by comparing the pre and posttreatment readings of Grummons and Ricketts analysis (Table 4 and Fig. 5). Maxillomandibular midline deviation was corrected by 1°, the lower midline shift to ANS-Me was also corrected. The difference in the readings of the right and left sides of the linear distance Co-Ag, Ag-Me, and Co-Me decreased by 1, 2, and 1 mm, respectively. Linear asymmetry assessment readings indicated the difference between the right and left sides of Co-MSR, Nc-MSR, J-MSR, and Ag-MSR decreased by 2 mm. This had been made possible by differential mandibular growth stimulation by loading differential forces by the unequal level of activations on both sides of the mandibular corrector. The treatment could thus accomplish maxillary and mandibular growth and a well-balanced orthognathic face along with a pleasant smile that could be well

appraised by superimpositioning the soft tissues and hard tissues in the lateral cephalograms (Fig. 9). The results were stable and extremely gratifying for both the clinician and the patient.

Contraindications

Patients who have a history of severe allergic reactions to nickel should not be treated with such an appliance.

Adverse Reactions

- Lower incisors become proclined.
- The pushing mechanism may cause intrusive forces on upper molars.
- Maxillary molars and mandibular canines may get distobuccal and mesiobuccal rotated, respectively.

Anchorage Control

The unwanted tooth movement that is commonly encountered with the appliance like proclination of lower anterior teeth or the opening of spaces distal to the canines, can be taken care of by using full slot rectangular stainless steel archwires (0.017" × 0.025" in 0.018" slot and 0.019" × 0.025" in 0.022" slot), the full lower arch figure of eight ligations, cinching off the lower archwire, using arch locks/stops posteriorly and second permanent molar inclusion. One should be prudent enough while selecting brackets and molar tubes to avoid such unnecessary tooth movements like significant negatively torque lower anterior brackets (−6° to −10°) should be chosen while bonding and upper 1st non-convertible molar tubes should be preferred. In the upper arch, we get a "Headgear effect" due to the distal force of the FFA, thus maintaining the planned incisor position (PIP) is of utmost importance.

Care to be Taken by Patients

Patients should be advised to intake a soft diet, to keep the device clean, and not to miss scheduled appointments.

CONCLUSION

Considering all the factors, we have tried to make an easy, efficient, and patient-friendly effort while treating the root cause of asymmetry. Though hybrid appliance was also a treatment of choice for such case, it demands a lot of compliance from the patient

side, thus this effort of ours to improve the facial imbalance up to an appreciable extent using differential force loading technique while being least troublesome for the patient may prove beneficial to harness excellent and satisfactory results with minimal efforts in such cases of mandibular retrusion with facial deformities and also decrease the need for surgical correction.

REFERENCES

1. Khumanthem S, Kumar M, Ansari A, et al. Correction of class II using PowerScope appliance – a case report. *Arch of Dent and Med Res* 2016;2(3):120–125.
2. Proffit WR. Malocclusion and dentofacial deformity in contemporary society. *Contemporary Orthodontics*. 4th ed., St. Louis: Mosby Elsevier; 2007. pp. 3–23.
3. McNamara JA. Components of class II malocclusion in children 8-10 years of age. *Angle Orthod* 1981;51(3):177–202. DOI: 10.1043/0003-3219(1981)0512.0.CO;2.
4. Kuo AA, Tritasavit S, John M, et al. Congenital muscular torticollis and positional plagiocephaly. *Pediatr Rev* 2014;35(2):79. DOI: 10.1542/pir.35-2-79.
5. Amin Y, Parameswaran R, Soundararajan Nagachandran K, et al. A hybrid myofunctional appliance for hemifacial hypertrophy – a case report. *J Dentofacial Anom Orthod* 2017;20(8):411. DOI: 10.1051/odfen/2017100.
6. Gandini P, Orsi L, Grampi B, et al. Functional approach with hybrid orthodontic appliances in mandibular asymmetries. *Mondo Ortod* 2008;33(4):229–238.
7. Vig PS, Vig KW. Hybrid appliances: a component approach to dentofacial orthopedics. *Am J Orthod Dentofac Orthod* 1986;90(4):273–285. DOI: 10.1016/0889-5406(86)90084-3.
8. Paulose J, Antony PJ, Suresh Kumar B, et al. PowerScope a class II corrector – a case report. *Contemp Clin Dent* 2016;7(2):221–225. DOI: 10.4103/0976-237X.183044.
9. Panherz H, Ruf S, Kohlhas P. Effective condylar growth" and chin position changes in Herbst treatment: a cephalometric roentgenographic long-term study. *Am J Orthod Dentofacial Orthop* 1998;114(4):437–446. DOI: 10.1016/s0889-5406(98)70190-8.
10. McNamara JA, Franchi L. The cervical vertebral maturation method: a user's guide. *Angle Orthodontist* 2018;88(2):133–143. DOI: 10.2319/111517-787.1.
11. Clarren SK, Smith DW, Hanson JW. Helmet treatment for plagiocephaly and congenital muscular torticollis. *J Pediatr* 1979;94(1):43–46. DOI: 10.1016/s0022-3476(79)80347-9.
12. Kharbanda OP, Sidhu SS, Sundaram KR. Cephalometric profile of north Indians: Tweed's analysis. *Int J Orthod* 1991;29(3-4):3–5.