

# Benefits of Using Low-level Laser Therapy in the Rapid Maxillary Expansion: A Systematic Review

Pi-Shan Lai<sup>1</sup>, Claudia Fierro<sup>2</sup>, Lorena Bravo<sup>3</sup>, Antonieta Perez-Flores<sup>4</sup>

## ABSTRACT

**Aim and objective:** Determine the benefits of low-level laser therapy (LLLT) as a complement to rapid maxillary expansion (RME), through a systematic review.

**Background:** Transversal maxillary compression is a common skeletal problem that can be treated with different devices. This RME technique consists of the separation and regeneration of the midpalatal suture. Low-level laser therapy has been suggested to be able to accelerate bone healing after trauma or bone defects.

**Review results:** Thirty-two publications were found by electronic search during July to August of 2019 on Medline (PubMed) and Google Scholar, using the terms "Low-Level Laser", "LLLT", "Rapid Maxillary Expansion", and "Osteogenesis Distraction". Only 16 were used (2 systematic reviews, 6 articles on humans, and 8 on animals). Even though all the studies had different intervention protocols, they all revealed that LLLT has the effect of accelerating bone regeneration after RME.

**Conclusion:** The use of LLLT as a complement to RME has shown promising results with cellular biostimulation, promoting angiogenesis and bone regeneration of the midpalatal suture.

**Clinical significance:** This study provides scientific evidence of the benefits of using LLLT as a complement to RME during orthopedic and orthodontic treatments, accelerating bone regeneration and reducing the time of consolidation of the maxillary.

**Keywords:** Low-level laser, Low-level laser therapy, Rapid maxillary expansion and osteogenesis distraction.

*International Journal of Clinical Pediatric Dentistry* (2021): 10.5005/jp-journals-10005-1966

## BACKGROUND

Rapid maxillary expansion (RME) is a technique used to correct transversal skeletal problems of the maxilla,<sup>1-3</sup> through the opening of the palatal suture, utilizing orthopedic forces with fixed intraoral devices. A controlled force is applied to the tooth and alveolar process,<sup>4</sup> allowing the complete separation of this suture and subsequent bone formation.<sup>4</sup> This is a slow process,<sup>5</sup> although the time required to complete its mineralization is not clear.<sup>6</sup> In general, a period of 3–6 months<sup>6,7</sup> of retention is indicated for correct ossification and maxillary stabilization,<sup>2</sup> thus avoiding repeated transverse compression.<sup>3-5</sup>

Currently, low-level laser therapy (LLLT) techniques have been applied to soft tissues<sup>2</sup> as a complement to other treatments, because it is a noninvasive technique that—with the application of low light energy—acts as a cellular "photo-modulator",<sup>1,8</sup> stimulating cell proliferation,<sup>9</sup> bone healing, and regeneration.<sup>3,5,8,10,11</sup>

This systematic review aims to determine the benefits of using LLLT as a complement to RME treatment.

## REVIEW RESULTS

A systematic review was performed during the months of July to August of 2019 in Medline (PubMed) and Google Scholar database, using the terms "Low-level Laser", "LLLT", "Rapid Maxillary Expansion", and "Osteogenesis Distraction". All texts available were consulted, as long as they had been published within the last 10 years. The last electronic search was completed on August 15, 2019.

The articles included in this study were:

- Studies <10-years-old (2009–2019)
- Investigations only on the maxillary rapid expansion (a simple disjunction or assisted by surgical intervention)

<sup>1-4</sup>Department of Pediatric Dentistry, Universidad de Concepcion, Concepcion, Bio Bio, Chile

**Corresponding Author:** Antonieta Perez-Flores, Department of Pediatric Dentistry, Universidad de Concepcion, Concepcion, Bio Bio, Chile, Phone: (+56-41) 2204386, e-mail: mperezf@gmail.com

**How to cite this article:** Lai P-S, Fierro C, Bravo L, *et al.* Benefits of Using Low-level Laser Therapy in the Rapid Maxillary Expansion: A Systematic Review. *Int J Clin Pediatr Dent* 2021;14(S-1):S98–S103.

**Source of support:** Department of Dental Pediatrics at the Universidad de Concepción

**Conflict of interest:** None

- Complementary application of LLLT to RME treatment
- Studies published in English or Spanish.

Exclusion criteria were:

- Studies >10-years-old (before 2009)
- Investigations with rapid mandibular expansion
- Clinical cases where patients had craniofacial alterations
- Duplicated studies.

## Study Selection

A total of 32 scientific articles were found through electronic research; 17 articles were retrieved through the MEDLINE database and 15 through Google Scholar, with the aforementioned keywords and with publication dates in the preceding 10-year period. During the screening process, 13 papers were removed because of duplication and 3 were deleted after reading the abstract, since it did not meet the criteria for inclusion, as they studied osteogenesis distraction of the mandible.

The number of articles that were finally included for data analysis was 16, after the removal of duplicated ones. The study flow diagram is presented in Flowchart 1.

### Study Characteristics

The studied articles consisted of clinical trials and laboratory studies on animal models.

The investigations on humans subjects focused on individuals between 8 years and 26 years of age. All of them used Hyrax devices for RME and some were surgically assisted. The number of participants ranged from 13 to 39 J/cm<sup>2</sup>, and only Abreu et al. described a clinical case.

The lasers utilized were mainly GaAlAs, with a wavelength of between 660 nm and 830 nm, with variable doses, time, and application rates in each study. In general, there were at least three zones of laser applications: incisive papilla and at the right and left side of the midpalatal suture.

The remaining eight studies were conducted on animal models, mainly rats between 11 weeks and 12 weeks old, while Santiago et al. focused on dogs instead. Applications of 780–940 nm laser and doses mainly of 18 J/cm<sup>2</sup>, located on the premaxilla.

Flowchart 1: Study flow diagram

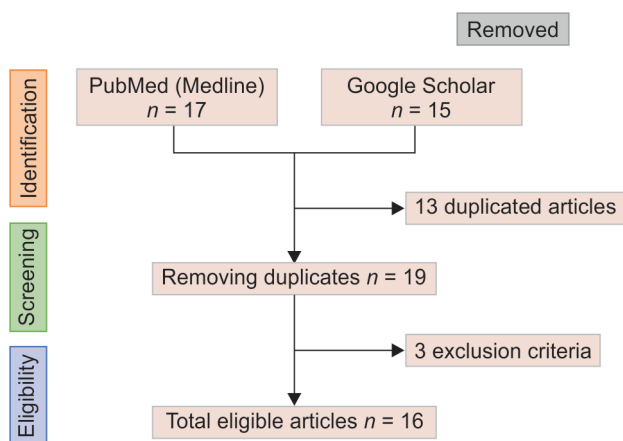


Table 1: Results obtained in human studies

Author (year)	N° subjects (average age)	Expansion	Consolidation	Measure method	Outcomes
Garcia et al. <sup>12</sup> (2016)	39 children (8.45 years)	Hyrax	6 months	CBCT	Greater cortical approach in irradiated patients
Abreu et al. <sup>7</sup> (2010)	1 adult (20 years)	Surgical + Hyrax	3 months	Occlusal X-ray	No edema or pain. Bone recovery from day 23. Complete bone regeneration at day 90
Moawad et al. <sup>13</sup> (2016)	24 adolescents (17.2–17.6 years)	Surgical + Hyrax	3 months	Cephalometric	The laser group presented major skeletal changes. LLLT as a complement to RME
Angeletti et al. <sup>6</sup> (2010)	13 adults (23.8–25.9 years)	Surgical + Hyrax	4 months	Periapical X-ray	LLLT accelerated bone regeneration, but optical bone density recovered only in the 7th month.
Ferreira et al. <sup>4</sup> (2016)	14 children (11 years)	Hyrax	4 months	CBCT	LLLT accelerates the process of ossification of the midpalatal suture, being complete in the 4th month, although it is not statistically significant.
Cepera et al. <sup>14</sup> (2012)	27 children (10.2 years)	Hyrax	3 months	Occlusal X-ray	LLLT accelerates the entire osteoblastic and osteoclast process. The irradiated group had higher bone density.

### Results of Individual Studies and Synthesis of Results

Tables 1 and 2 show the authors and their studies in human trials, where most researchers used Hyrax devices, with an average maintenance of 3–4 months. Low-level laser therapy was applied in 8–12 sessions, always with at least two irradiation zones, one on the anterior portion of the palatal midline and another in the posterior one. In addition to the two lateral zones, one at each side of the midpalatal suture.

Tables 3 and 4 show the studies that were carried out on animals, usually rats. At the end of the research period, euthanasia was performed on all subjects under study to be able to complement the results with histological analysis. In general, the investigations lasted a short period, on average approximately 1 month and the preferred zone for irradiation was at the interincisive papilla, by palatine.

### DISCUSSION

All authors, shown in Tables 1 to 4, have demonstrated that the use of LLLT as a complement to RME treatment is beneficial for patients since it accelerates the bone regenerative process. According to Skondra et al.,<sup>15</sup> this is due to the capacity of the low-level laser that penetrates the hypodermis and can be absorbed by the cytochrome C oxidase enzymes in the mitochondria, generating a biostimulation cascade in the endothelial, osteoblastic, and osteoclast cells,<sup>15</sup> and thereby a larger amount of vascular formation and osteoblastic activity. This affirmation has been supported by the authors: Aras et al.,<sup>3</sup> Santiago et al.,<sup>2</sup> Da Silva et al.,<sup>9</sup> Rosa et al.,<sup>1,7</sup> among others.<sup>11</sup>

Rosa et al.<sup>8</sup> concluded that the use of LLLT accelerates the process of bone repair and regeneration by observing that in the first 7 days of expansion and irradiation, the groups affected by LLLT had a higher concentration of osteoclasts than the control group (without irradiation); however, over time and at the end of the experiment, the group exposed to laser presented a higher concentration of osteoblasts and capillaries and a smaller amount of osteoclasts than the control group. Similar results were described by Da Silva et al.,<sup>9</sup> who reported that the use of LLLT doubles the rate of cell proliferation, due to the increased

**Table 2:** Comparative table between LLLT used in human subjects

Author (year)	Type of laser	Wavelength (nm)	N° sessions (Applications × time)	Dose (J/cm <sup>2</sup> )	Time of irradiation	Sites
Garcia et al. <sup>12</sup> (2016)	InGaAlP	660	7 sessions (1 per week)	23/12	60 seg intrasutural, 30 seg extrasutural, Total: 300 seg.	6 zones: Middle palatal suture: (1 vestibular and 3 palatine) and Lateral to middle palatal Raphe (right and left)
Abreu et al. <sup>7</sup> (2010)	Infrared	824	8 sessions (1 every 48 hours)	1.5	20 seg per site, Total: 140 seg	7 zones: Infraorbital foramen, nasal wing, nasopalatine foramen. Nasopalatine suture and transverse palatal suture
Moawad et al. <sup>13</sup> (2016)	Erbium-YAG	Not specified	3 sessions (1 per month)	Not specified	5 seg per site, total: 40 seg	8 zones on the midpalatal suture
Angeletti et al. <sup>6</sup> (2010)	GaAlAs	830	8 sessions <ul style="list-style-type: none"> <li>• 24 hours post-operation</li> <li>• Next: 1 every 48 hours</li> </ul>	140	84 seg per site, Total: 252 seg.	3 zones: Interincisive papilla (palatine) and 2 mm per side of the palatine midline.
Ferreira et al. <sup>4</sup> (2016)	GaAlAs	780	12 sessions <ul style="list-style-type: none"> <li>• 1era mes: 2 c/ semana</li> <li>• 2do mes: 1 c/ semana</li> </ul>	Not specified	20 seg per site, total: 80 seg.	4 zones: Incisive papilla (palatine), lateral to middle palatal raphe (right and left) and middle posterior raphe
Cepera et al. <sup>14</sup> (2012)	Diode	780	11 sessions: activation for 5 days. After activation ended, irradiation for 3 days. Then 1 per week × 3 weeks	10	10 seg per site, Total: 100 seg	10 zones: Anterior to Hyrax device: 2 on the middle line and 1 each side; Middle zone: 1 each side and Posterior zone: 2 on the midline and 1 each side

**Table 3:** Results obtained in animal studies

Author (year)	No. of subjects (average age)	Expansion	Consolidation	Outcomes
Aras et al. <sup>3</sup> (2015)	32 rats (12 weeks)	7	10 days	The irradiated group had a higher concentration of osteoblasts and capillaries, but fewer osteoclasts than the control group
Tas Deynek and Ramoglu <sup>10</sup> (2019)	18 rats (11–12 weeks)	7	21 days	The groups with lower potency had a higher concentration of osteoblasts, osteocytes, blood vessels, and new bone tissue, they also had reduced inflammation areas. Although the differences with those of higher intensity were not statistically significant
Santiago et al. <sup>2</sup> (2012)	11 dogs (6 months)	7	33 days	The irradiated group presented connective tissues, bone, and blood vessels with similar distribution to the group without expansion, however, the group with expansion only presented perpendicular connective tissue and less mature fibers
Da Silva et al. <sup>9</sup> (2010)	30 rats	1	7 days	LLLT accelerates twice the time of cellular proliferation. LLLT increases the expression of mRNA of ALP, Runx2, OC, COL, and BSP. The peak of the effect of LLLT occurs <i>in vivo</i> cells around 48 hours
Aras et al. <sup>3,17</sup> (2015)	32 rats (12 weeks)	7	10 days	The group with LLLT had a higher concentration of osteoclasts on the 7th day, in addition to a greater thickness of trabeculated bone tissue. On the 17th day, the irradiated group presented better ossification than the control group
Amini et al. <sup>5</sup> (2015)	78 rats	7	23 days	Both groups lost weight, but it was less in the irradiated group, who on the 7th day began to regain their initial weight. The same happened in the control group, but on the 9th day. Although the radiate was stopped on the 15th day, on the 30th day, the LLLT group showed greater regeneration than the control group
Rosa et al. <sup>1</sup> (2016)	45 rats (6 weeks)	7–14	No	LLLT induces changes in osteoblast activity, while LED increased cell growth in several cells (fibroblasts and osteoblasts)
Rosa et al. <sup>8</sup> (2013)	20 rats	8	No	LLLT did not show significant differences with LED in the amount of collagen deposition, but there were significant differences in the group irradiated with LED, who presented greater bone mineralization



**Table 4:** Comparative table between LLLT used in animal subjects

<i>Author (year)</i>	<i>Type of laser</i>	<i>Wavelength (nm)</i>	<i>No. of sessions (Applications × time)</i>	<i>Dose (J/cm<sup>2</sup>)</i>	<i>Time of irradiation</i>	<i>Zones</i>
Aras et al. <sup>3</sup> (2015)	GaAlAs	808	4 sessions (daily until the 4th day of expansion)	5	20 seg	Premaxilla
Tas Deynek and Ramoglu <sup>10</sup> (2019)	InGaAsP	940	6 sessions (2 per week)	18, 42, and 60	180 seg	Incisive papilla, between the incisal edge, almost parallel to the mid-palatal suture
Santiago et al. <sup>2</sup> (2012)	Not specified	790–904	20 sessions (1 every 48 hours)	90–120	Not specified	4 zones are distributed bilaterally and parallel to the palatal mid-suture
Da Silva et al. <sup>9</sup> (2010)	AsGaAl	830	1 session immediately after expansion	160	0.42 seg	Incisive papilla, between the incisal edge, almost parallel to the mid-palatal suture
Aras et al. <sup>3,17</sup> (2015)	GaAlAs	808	4 sessions (daily until the 4th day of expansion)	5	20 seg	Premaxilla
Amini et al. <sup>5</sup> (2015)	GaAlAs	810	8 sessions (1 every 48 hours)	4	Not specified	4 zones: 0.5 mm, 1 mm, 2 mm and 3 mm apical from the edge of the bone crest.
Rosa et al. <sup>1</sup> (2016)	Diodes LED	780	6 sessions (1 every 48 hours)	18	120 seg	Incisive papilla, between the incisal edge, almost parallel to the mid-palatal suture.
Rosa et al. <sup>8</sup> (2013)	Diodes/LED	780/850	3 sessions (1 every 48 hours)	18	257/120 seg	Incisive papilla, between the incisal edge, almost parallel to the mid-palatal suture.

expression of mRNA ALP, Runx<sub>2</sub>, OC, COL, and BSP, all of which stimulates the phenotype of osteoblast cells, favoring a much faster formation of mineralized matrix. Santiago et al.<sup>2</sup> added that the use of LLLT leads to a proper distribution of connective tissue, bone, and blood vessels, similar to healthy tissues (without RME). Alternatively, the subjects that had RME without irradiation had a different tissue distribution, in which the connective matrix was spread perpendicular and with few mature collagen fibers, unlike the experimental group.

Although it has been shown that the use of a lower-power laser improves bone regeneration results, there is still no consensus regarding the dose needed to obtain the desired results. According to the law of Arndt-Schultz,<sup>10,16</sup> there is a therapeutic window of the effective dose range, due to the different stimulus intensities, they can increase or decrease physiological functions. In addition, it is reported that lower levels of stimuli increase physiological functions, while high-intensity stimulation can decrease and even inhibit them.<sup>16</sup> The results obtained by Tas Deynek and Ramoglu<sup>10</sup> confirms the theory of the therapeutic window, where the authors observed that the best reparative effects on rats were obtained at a lower dose (18 J/cm<sup>2</sup>), with a higher initial concentration of osteocytes, subsequent increase of osteoblasts, blood vessels,

and new bone tissue. By contrast, groups who received higher doses of radiation showed increased inflammation and decreased regeneration.

Another concern regarding the use of LLLT as a complementary therapy has been the frequency with which it should be applied. Some authors have described the use of low-level laser: once a day initially and later every 48 hours,<sup>6</sup> others have only indicated once or twice a week.<sup>4,10,12,14</sup> A single application has also been mentioned<sup>9</sup> in other studies. Despite the variety that has been observed, researchers like Tas Deynek and Ramoglu,<sup>10</sup> Santiago et al.,<sup>2</sup> Da Silva et al.,<sup>9</sup> Aras et al.,<sup>3,17</sup> Amini et al.,<sup>5</sup> and Rosa et al.<sup>1,8</sup> have concluded that the use of LLLT at early stages facilitates the healing process, regardless of the amount of irradiation time applied. Aras et al.<sup>3,17</sup> showed that with a single laser session, the rats that were sacrificed on the 17th day had a higher amount of trabeculated tissue and greater ossification than the control group.<sup>16</sup> On the other hand, Amini et al.<sup>5</sup> demonstrated that the effect of LLLT is cumulative, so there were no significant differences during the first week, but there were in subsequent weeks. Even though the researchers stopped applying LLLT on day 15, they observed that on day 30 there were better results than in the other groups. Da Silva et al.<sup>9</sup> described that the peak of laser effectiveness was 48

hours after its application and that it could persist for 17 days, which were the number of days that the *in vitro* study lasted.

As seen previously, the use of LLLT increases local vascularity and perfusion, accelerating the regenerative process, depending on the dose, time, and irradiation method. That is why Santiago et al.<sup>2</sup> affirmed that the use of LLLT in combination with RME could reduce the consolidation time of the device, by accelerating the repair process in the midpalatal sutures. Mollaei et al.<sup>5</sup> obtained similar results, observing that the use of LLLT shortened the initial inflammatory reaction and lead to the formation of a new bone matrix within 15 to 45 days. Though the results mentioned above were obtained in animal studies, researchers Abreu et al.<sup>7</sup> and Ferreira et al.<sup>4</sup> provide further evidence of the previous statements through their respective studies on human subjects.

Abreu et al.<sup>7</sup> demonstrated in their case study that there is complete regeneration at the third month after RME, while Ferreira et al.<sup>4</sup> obtained them within 4 months. In contrast, Angeletti et al.<sup>6</sup> observed similar results only in the seventh month. These differences could be mainly due to two factors: first, the number of sites irradiated per session. Abreu et al.<sup>7</sup> were the ones that obtained the best results, within 3 months, possibly to the largest number of areas irradiated per session, instead, Angeletti et al.<sup>6</sup> used LLLT only in three zones. On the other hand, it is also worth noting the difference in age among the studied subjects, where Ferreira et al.<sup>4</sup> focused on student patients (11 years), while Angeletti et al.<sup>6</sup> on young adults (24–26 years). This last factor can play a crucial role during the repair and regeneration process, since at a younger age there is a better cellular response, as it has a greater capacity and speed of differentiation.

Among the 16 selected publications, only 3 authors<sup>5,8,15</sup> indicated the usefulness of LLLT to reduce the level of pain in patients undergoing RME. According to Amini et al.<sup>5</sup> by irradiating patients with LLLT, it could increase the production of prostaglandin, which influences coagulation and hemostatic and decrease infections, calming the pain and local trauma. Nonetheless, more research on this area is required.

At last, Rosa et al.<sup>1,8</sup> conducted RME studies with LLLT or LED as a compliment, to determine the effectiveness of each type of radiation. From the results obtained, no significant differences were observed,<sup>1</sup> but they did notice that the use of LLLT generated changes in osteoblasts,<sup>8</sup> while LED allowed the increase of cell growth, both of fibroblasts and osteoblasts and therefore greater mineralization.<sup>1,8</sup>

Even though this review has shown that LLLT has had promising effects in promoting bone regeneration and healing after midpalatal suture expansion, we must recognize that the provided literature does not provide high-level evidence, nor do we have long-term studies.

## CONCLUSION

This review showed that the use of LLLT as a complement to the RME procedure improves the speed of bone repair and regeneration to a significant degree. The use of LLLT is therefore recommended beginning from early stages, through small doses, and on at least four sites of the palatal suture. In addition, LLLT should be applying frequently, since its effect is cumulative.

Although there are some studies where LLLT was used to reduce pain in patients with RME, there is not much evidence in this area regarding its actual effectiveness and there are not standardized

application protocols at this time. For this reason, we suggest further studies focusing on these research questions specifically.

## CLINICAL SIGNIFICANCE

This study provides scientific evidence of the benefits of using LLLT as a complement to RME during orthopedic and orthodontic treatments.

## REFERENCES

- Rosa CB, Habib FAL, de Araújo TM, et al. Laser and LED phototherapy on mid palatal suture after rapid maxilla expansion: Raman and histological analysis. *Lasers Med Sci* [Internet] 2016;32(2):263–274. DOI: 10.1007/s10103-016-2108-3.
- Santiago VCCE, Piram A, Fuziy A. Effect of soft laser in bone repair after expansion of the midpalatal suture in dogs. *Am J Orthod Dentofac Orthop* [Internet] 2012;142(5):615–624. DOI: 10.1016/j.ajodo.2012.05.015.
- Aras MH, Bozdog Z, Demir T, et al. Effects of low-level laser therapy on changes in inflammation and the activity of osteoblasts in the expanded premaxillary suture in an ovariectomized rat model. *Photomed Laser Surg* 2015;33(3):136–144. DOI: 10.1089/pho.2014.3820.
- Ferreira FNH, Gondim JO, Neto JJSM, et al. Effects of low-level laser therapy on bone regeneration of the midpalatal suture after rapid maxillary expansion. *Lasers Med Sci* [Internet] 2016;31(5):907–913. DOI: 10.1007/s10103-016-1933-8.
- Mollaei M, Najaf Abadi M, Amini F. Evaluating the effect of laser irradiation on bone regeneration in midpalatal suture concurrent to rapid palatal expansion in rats. *J Orthod Sci* 2015;4(3):65. DOI: 10.4103/2278-0203.160237.
- Angeletti P, Pereira MD, Gomes HC, et al. Effect of low-level laser therapy (GaAlAs) on bone regeneration in midpalatal anterior suture after surgically assisted rapid maxillary expansion. *Oral Surg, Oral Med Oral Pathol Oral Radiol Endodontol* 2010;109(3):e38–e46. DOI: 10.1016/j.tripleo.2009.10.043.
- Abreu ME, Viegas VN, Pagnoncelli RM, et al. Infrared laser therapy after surgically assisted rapid palatal expansion to diminish pain and accelerate bone healing. *World J Orthod* 2010(September <https://www.researchgate.net/publication/46579831%0AInfrared>).
- Rosa CB, Habib FAL, De Araújo TM, et al. Effect of the laser and light-emitting diode (LED) phototherapy on midpalatal suture bone formation after rapid maxilla expansion: a Raman spectroscopy analysis. *Lasers Med Sci* 2013;29(3):859–867. DOI: 10.1007/s10103-013-1284-7.
- Da Silva APRB, Petri AD, Crippa GE, et al. Effect of low-level laser therapy after rapid maxillary expansion on proliferation and differentiation of osteoblastic cells. *Lasers Med Sci* 2012;27(4):777–783. DOI: 10.1007/s10103-011-0968-0.
- Tas Deynek G, Ramoglu SI. Effects of different settings for 940 nm diode laser on expanded suture in rats. *Angle Orthod* 2019;89(3):446–454. DOI: 10.2319/052318-392.1.
- Davoudi A, Amrolahi M, Khaki H. Effects of laser therapy on patients who underwent rapid maxillary expansion; a systematic review. *Lasers Med Sci* 2018;33(6):1387–1395. DOI: 10.1007/s10103-018-2545-2.
- Garcia VJ, Arnabat J, Comesaña R, et al. Effect of low-level laser therapy after rapid maxillary expansion: a clinical investigation. *Lasers Med Sci* 2016;31(6):1185–1194. DOI: 10.1007/s10103-016-1970-3.
- Moawad SG, Bouserhal J, Al-Munajed MK. Assessment of the efficiency of Erbium-YAG laser as an assistant method to rapid maxillary expansion: an in vivo study. *Int Orthod* 2016;14(4):462–475. DOI: 10.1016/j.ortho.2016.10.015.
- Cepera F, Torres FC, Scanavini MA, et al. Effect of a low-level laser on bone regeneration after rapid maxillary expansion. *Am J Orthod Dentofac Orthop* 2012;141(4):444–450. DOI: 10.1016/j.ajodo.2011.10.023.



15. Skondra FG, Koletsi D, Eliades T, et al. The effect of low-level laser therapy on bone healing after rapid maxillary expansion: a systematic review. *Photomed Laser Surg* 2017;36(2):61–71. DOI: 10.1089/pho.2017.4278.
16. Mednaturis [Internet]. Madrid; 2019 [citado 29/8/2019] Enciclopedia de Medicina Taturista. Ley de Arndt-Schulz [aprox. 1 pantalla]. Disponible en: <http://www.mednaturis.com/ficha-termino.php?idtermino=74&ret=terminos.php>.
17. Aras MH, Erkilic S, Demir T, et al. Effects of low-level laser therapy on osteoblastic bone formation and relapse in an experimental rapid maxillary expansion model. *Niger J Clin Pract* 2015;18(5):607. DOI: 10.4103/1119-3077.154218.