

Evaluation of Clinical Effectiveness and Patient Acceptance of Hall Technique for Managing Carious Primary Molars: An *In Vivo* Study

Hind P Bhatia¹, Puneet M Khari², Shveta Sood³, Naresh Sharma⁴, Akshara Singh⁵

ABSTRACT

Introduction: Hall technique (HT) is a biological approach where decay is sealed under preformed metal crowns without any caries removal, tooth preparation or local anesthesia. Dental caries is one of the most common prevailing chronic condition that affect both adults and children. Since children are anxious and apprehensive to dental treatment, their uncooperative behavior might cause hindrance in the treatment, which often leads to manage them in general anesthesia. To better address the dental care needs in pediatric patients, dental surgeons require some alternatives for management of caries and restorative treatment in children. The Hall technique is one such conservative treatment approach developed by Dr Norna Hall in 1980s.

Aim: The purpose of this study was to assess the clinical effectiveness and patient acceptance of Hall technique for managing carious primary molars.

Materials and methods: 84 children in the age group 6–10 years with class I and class II carious lesions limited to dentin were selected for the study. Occlusal vertical dimension (OVD) was measured preoperatively, postoperatively and after 6 months. Discomfort level was assessed by facial pain rating scale and by questionnaires filled on the day of placement of SS crown, 1 week after placement and 6 months after placement.

Results: The Hall technique was found to be successful, as there was no failure clinically as well as radiographically within 6 months of placement of SS crown. The increased OVD postoperatively returned to its normal values within 6 months, the mean change in the OVD was found to be statistically significant ($p = 0.02$).

Conclusion: The Hall technique proved to be clinically effective and acceptable by maximum number of children.

Keywords: Dental caries, Occlusal vertical dimension, Stainless steel crowns, Wong-Baker faces pain rating scale.

International Journal of Clinical Pediatric Dentistry (2019): 10.5005/jp-journals-10005-1699

INTRODUCTION

Dental caries is one of the most common prevailing chronic condition that affects both adults and children.¹ No doubt, there exist a lot of treatment modalities to treat dental caries, but sometimes in children, it is very problematic. Since children are anxious and apprehensive to dental treatment, their uncooperative behavior might cause hindrance in treatment, which often leads to manage them under general anesthesia.²

The advent of newer materials and techniques has led to a paradigm shift in caries management. Emphasis is being laid more on biological approaches as opposed to conventional drill and fill philosophy.

Conventional treatment includes excavation or removal of the infected dental tissues, followed by restoration with a suitable filling material. This approach to treating dental caries is invasive, as it may involve the removal of a considerable amount of sound tooth structure for access to the carious lesion.³ Also, the failure of conventional restorations is common in younger children due to the anatomy of primary teeth and limited cooperation of child patients, thereby leading to difficulty in placement of restorations.⁴ This can lead to an increase in the number of appointments and turn the cost. Also, the high-pitched noise of the air rotor produces a synergistic effect on the anxiousness of the pediatric patient. To better address dental care needs in pediatric patients, dental surgeons require some alternatives for management of caries and restorative treatment in children.

The Hall technique (HT) is one such conservative treatment approach developed by Dr Norna Hall in the 1980s. This technique involves the use of preformed stainless steel (SS) crowns to seal

¹⁻⁵Department of Pedodontics and Preventive Dentistry, Manav Rachna Dental College, Faridabad, Haryana, India

Corresponding Author: Akshara Singh, Department of Pedodontics and Preventive Dentistry, Manav Rachna Dental College, Faridabad, Haryana, India, Phone: +91 9818852093, e-mail: akshara.agra@gmail.com

How to cite this article: Bhatia HP, Khari PM, Sood S, *et al.* Evaluation of Clinical Effectiveness and Patient Acceptance of Hall Technique for Managing Carious Primary Molars: An *In Vivo* Study. *Int J Clin Pediatr Dent* 2019;12(6):548–552.

Source of support: Nil

Conflict of interest: None

over carious lesions using glass ionomer luting cement. The Hall technique requires no administration of local anesthesia, no caries removal, and also no crown preparation, which makes it more acceptable to pediatric patients as well as to their parents.⁵ It also helps the clinicians to limit the anxiety of a pediatric patient, thereby making them more cooperative. Hall technique is a child-centered approach minimally invasive approach and can be expected to cause less discomfort than conventional treatment approaches.⁶

MATERIALS AND METHODS

The study sample was selected from the outpatient Department of Pedodontics and Preventive Dentistry, Manav Rachna Dental College, Faridabad, Haryana, India. Eighty-four children of age group

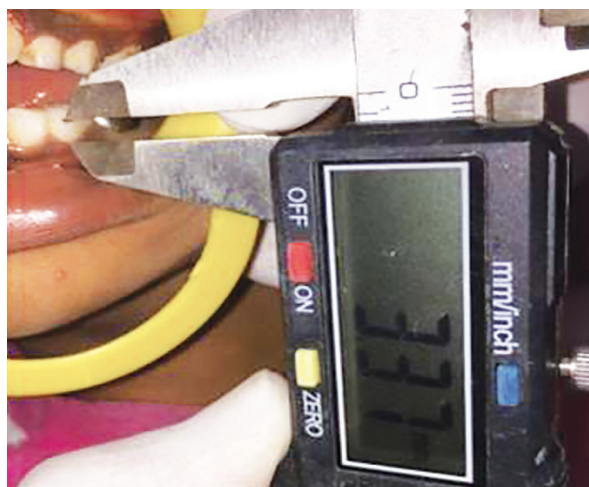

Fig. 1: Occlusal vertical dimension measurement with the help of digital Vernier caliper

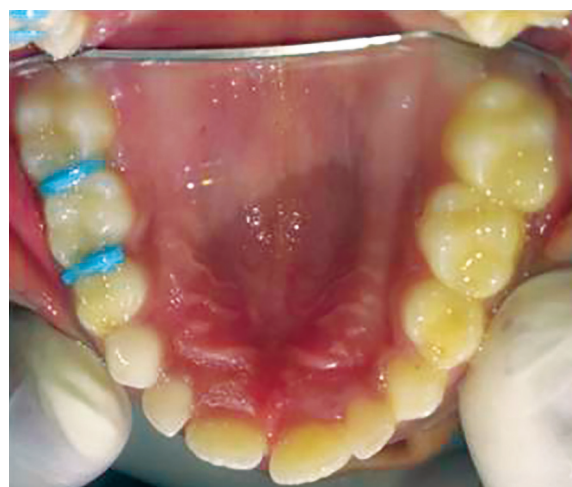

Fig. 2: Separators placement

6–10 years who met the inclusion criteria were selected. Children exhibiting cooperative behavior, and whose parents/guardians signed the informed consent form were part of the research. The key consideration was at least one primary molar with class I and class II carious lesions limited to dentin, asymptomatic tooth with no history of pain, fully erupted primary teeth. Exclusion criteria were the presence of partially erupted primary teeth, insufficient sound tooth structure left to retain the crown, irreversible pulpal involvement or dental abscess, children with tooth mobility, and children having bruxism. The protocol of the study was reviewed and approved by the Research Ethical Committee.

Result	Criteria for results
Successful	<ul style="list-style-type: none"> No clinical sign and symptom of pulpal pathology No pathology visible on radiographs No intervention required
Unsuccessful	<ul style="list-style-type: none"> Crown perforation New caries around margins Reversible pulpitis Irreversible pulpitis or dental abscess Interradicular radiolucency Internal root resorption

The operator carried out an intraoral examination using a mouth mirror and explorer to assess the depth of the carious lesion. Teeth with caries limited to occlusoproximal surfaces and extending to dentin were selected for the study. Oral prophylaxis was done to remove any debris or calculus present on the tooth if required. Preoperative occlusal vertical dimension (OVD) was measured using a digital vernier caliper (DANIU) (Fig. 1). The treatment was carried out according to the Hall technique (HT) protocol of Innes et al.⁷ The airway of the child was protected properly by upright seating of the patient or by placing a gauze swab between the tongue and the tooth or by securing the crown with the floss. Next, the appropriate size of the preformed SS crown was selected, which covered all the cusps and approached the contact points, with a slight feeling of “spring back.” In case of open contacts, the crown was placed in the same visit, but if contact points were closed, orthodontic separators were placed with separator placing plier, to gain the required space

(Fig. 2). The patient was recalled after 3–4 days for placement of SS crown. No tooth preparation was done, and no alteration was performed on the crown. The smallest possible precontoured, pretrimmed, and precrimped SS crown (3m ESPE) was selected and cemented on the tooth using glass ionomer cement (GC type I) (Fig. 3). Excess cement was cleared immediately using a straight probe after cementation. Postoperative OVD was recorded again to measure the change. After 6 months, caries progression and OVD were assessed using digital IOPA radiograph (Fig. 4) and digital Vernier caliper, respectively.

Following criteria were followed for clinical and radiographic assessment:

A questionnaire was given along with Wong-Baker faces pain rating scale (Fig. 5) and explained to assess the discomfort level observed by the child. The questionnaire was filled thrice that is on the day of placement of SS crown after 1-week follow-up and after 6 months follow-up.

RESULTS

Statistical analysis was performed using SPSS software version 23. The mean value of OVD before treatment was 3.34 mm, which increased to 4.36 mm postoperatively. After 6 months follow-up, the mean value decreased to 3.66 mm. After statistical analysis, the *p* value was 0.02. The result obtained showed that the OVD, which increased after the placement of the SS crown, decreased significantly, and reverts to its normal range after 6 months. Table 1 shows the mean values of OVD preoperative, postoperative, and 6 months after placement of SS crown. There were no clinical failures among all 84 children. At the time of 6 months follow-up, 100% of the crowns placed by HT were successful, and no further treatment, either pulp therapy or restoration was required. Also, when examined radiographically after 6 months, no periapical changes were seen in any of the 84 patients. When assessed the comfort level of all 84 cases by Wong-Baker faces pain rating scale, 33 cases (39%) faced little discomfort while the placement of SS crown and 22 patients (26%) experienced no pain or discomfort (Fig. 6). Tables 2 to 4 shows acceptability of the technique by rating the answers marked by children in questionnaire 1, 2, 3. To check the acceptability of HT, questionnaire filled by the children were evaluated. All three questionnaires were evaluated separately, and the statistical analysis was done, the *p* values came out to be 0.04,

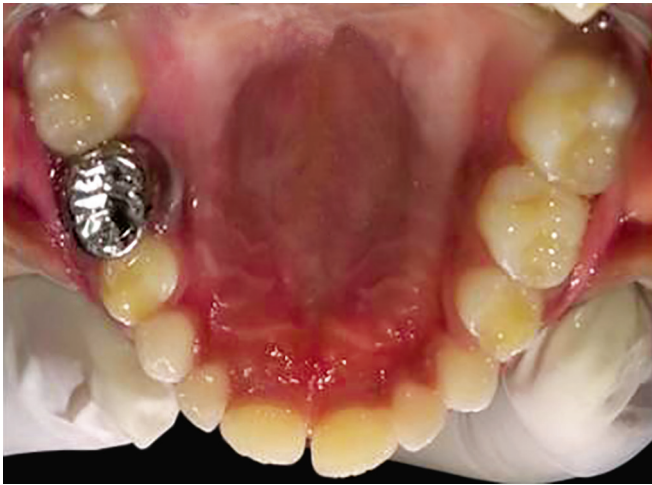

Fig. 3: SS crown placement

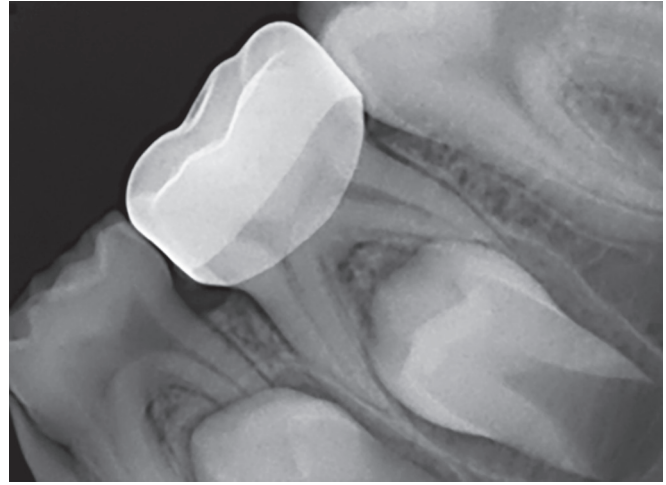


Fig. 4: Six months postoperative digital intraoral periapical image

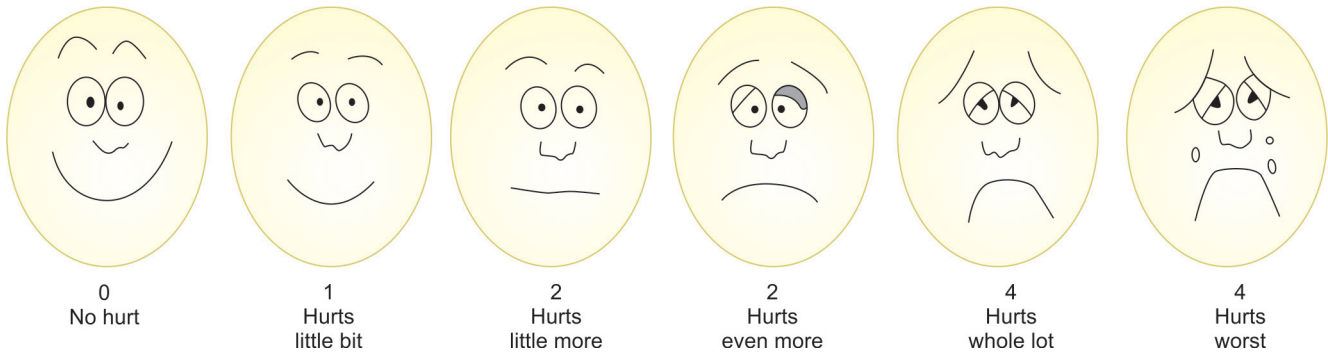


Fig. 5: Wong-Baker faces pain rating scale

Table 1: Comparison of OVD pretreatment, posttreatment and 6 months after treatment

ANOVA: single factor summary				
Groups	Count	Sum	Average (a)	Variance
PreOVD	84	280.95	3.34	0.99
PostOVD	84	366.25	4.36	1.28
OVD after	84	307.63	3.66	1.06
Difference in OVD	84	58.62	0.70	0.13

ANOVA						
Source of variation	SS	df	MS	F	p value	F crit
Between groups	647.31	3.00	215.77	249.75	0.02	2.63
Within groups	286.83	332.00	0.86			
Total	934.15	335.00				

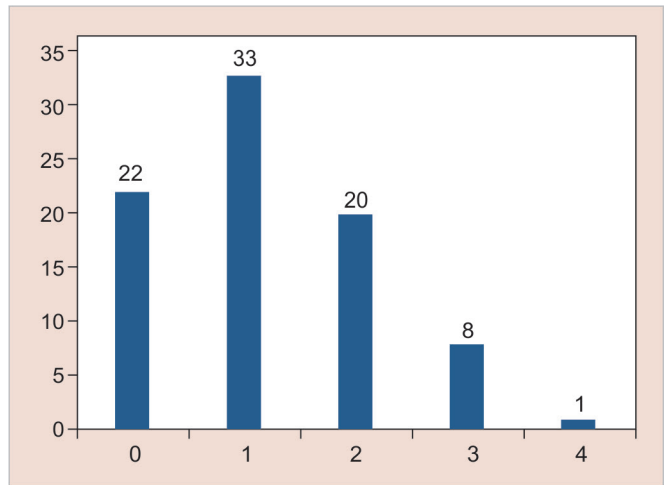


Fig. 6: Distribution of comfort level assessed by Wong-Baker faces pain rating scale

0.02, and 0.04, respectively, which showed that the HT was accepted favorably by the children.

DISCUSSION

McElroy had beautifully stated that “Although operative dentistry may be perfect, the appointment is a failure if a child departs in tears.” It stresses the importance of behavior management over technical excellence in pediatric dentistry.⁸ Dental anxiety

is “a feeling of apprehension about dental treatment that is not necessarily connected to a specific external stimulus.” Fear and anxiety are often associated with the child’s first dental visit and have a negative impact on child’s psychology making the dental appointment an unpleasant one.⁹

Dental anxiety leads to increase the pain perception of the pediatric patient, irrespective of the anesthetic devices used. Conversely, uncomfortable dental treatments can also result in



Table 2: Acceptability of the technique by rating the answers marked by children in questionnaire 1

ANOVA: single factor summary				
Groups	Count	Sum	Average	Variance
Q1	84	123	1.46	0.25
Q2	84	123	1.46	0.25
Q3	84	121	1.44	0.25
Q4	84	126	1.50	0.25

ANOVA						
Source of variation	SS	df	MS	F	p value	F crit
Between groups	0.15	3.00	0.05	0.20	0.04	2.63
Within groups	83.49	332.00	0.25			
Total	83.64	335.00				

Table 3: Acceptability of the technique by rating the answers marked by children in questionnaire 2

ANOVA: single factor summary				
Groups	Count	Sum	Average	Variance
Q1	84	104	1.24	0.18
Q2	84	138	1.64	0.23
Q3	84	138	1.64	0.23
Q4	84	53	0.63	0.96

ANOVA						
Source of variation	SS	df	MS	F	p value	F crit
Between groups	57.63	3.00	19.21	47.82	0.02	2.63
Within groups	133.37	332.00	0.40			
Total	191.00	335.00				

increased dental anxiety. It is important to reduce anxiety not only in the highly anxious patient who avoids dental care but also in patients who undergo regular dental care in spite of being anxious. The target of any dental treatment should be to prevent the patient from adopting negative dental care behavior.⁹

For past decades, carious primary molars are being treated by conventional “drill and fill” philosophy, that is, give local anesthesia to the child by injection, drill the carious tissue out using a high and slow speed drill, restore the primary tooth with a restorative material. Conventional restoration of primary teeth has shown only moderate outcomes depending on the techniques and materials used and the ability of children to cooperate because of age or other factors. Even if the behavior and cooperation for treatment in children are ideal, the restoration of their teeth would still be a technically demanding exercise due to the size and morphology of the primary teeth.¹⁰

With the focus shifting on biological approaches for restoration of carious teeth, newer techniques have evolved in the recent past. One such revolutionary concept is the Hall technique. The “Hall Technique” was originally pioneered by dental practitioner Norna Hall in Scotland in response to an overwhelming amount of caries in the children. Dental caries is a disease which results from an ecological shift within the dental biofilm with a dominance

Table 4: Acceptability of the technique by rating the answers marked by children in questionnaire 3

ANOVA: single factor summary				
Groups	Count	Sum	Average	Variance
Q1	84	164	1.95	0.05
Q2	84	164	1.95	0.05
Q3	84	6	0.07	0.12
Q4	84	155	1.85	0.88

ANOVA						
Source of variation	SS	df	MS	F	p value	F crit
Between groups	215.15	3.00	71.72	264.03	0.04	2.63
Within groups	90.18	332.00	0.27			
Total	305.33	335.00				

of acidogenic and aciduric microorganisms. The Hall technique manipulates the plaque environment by sealing the tooth, separating it from the substrates, which were normally received from the oral environment.⁷ Stainless steel crowns are still underutilized in various countries, and many of the dental surgeons are not familiar with the HT.¹¹ HT has been found to be durable and economical treatment option for treating carious primary molars. HT is preferred over more invasive treatment options but requires proper case selection and pulpal status diagnosis.¹² Study conducted by Santamaria et al. favors HT as an alternative management option for primary molars. It has been shown to perform better than nonrestorative caries treatment such as fluoride varnish and conventional restorations.¹³ This study was undertaken with the aim of checking the clinical effectiveness and acceptability of the Hall technique.

The study included 84 children in the age group of 6–10 years. Standard technique, as proposed by Innes et al.,⁷ was used to place SS crown. Follow-up was done at 1-week and 6 months.

Van der Zee et al. evaluated the effect of HT on OVD in primary dentition *in vivo* and concluded that the occlusion returned to pretreatment levels after 15–30 days.⁶ Similarly, 84 cases in the present study showed that the OVD, which was increased after the placement of the SS crown nearly established to its original value at 6 months follow-up. The occlusion equilibrates quite rapidly, usually in a matter of weeks. The mean of pretreatment OVD was 3.34 mm, mean of posttreatment OVD was 4.36, and mean of the 6-month interval was 3.66. After statistical analysis, the *p* value was 0.02, which shows significant effects of the Hall technique by measuring OVD at various time intervals.

Innes et al. conducted a randomized control study with a sample size of 132 child patients and concluded that there were no clinical or radiographic signs of pulpal pathosis. One lesion was randomly treated, using the HT and the other was randomly treated conventionally (mostly by glass ionomer cement). The results were an outstanding success rate of 98% for the Hall SSC when compared to the control restorations.¹⁴

Study done by Clark et al. reported evidence of high clinical and radiographic success rates.¹⁵ In the presented study also, no clinical and radiographic failure was observed after 6 months follow-up.

Although the quantitative data display an overall positive experience for patients, but some patients suggest that certain aspects of treatment may have an occasion been painful.

According to study done by Page et al., an inductive approach was used to analyze the qualitative data and information was arranged into several categories based on the key themes, which arose. Children treated with the HT were asked immediately after treatment whether they had enjoyed their visit to the clinic that day, and nearly 90% responded positively. Common themes were found with regard to appearance, pain, the procedure, and general questions on acceptability, but overall there was a high degree of acceptance among both parents and children for the technique.¹⁶

Research done by BaniHani et al. concluded that the HT approach is accepted favorably by the children and carers and is also associated with reduced treatment costs.¹⁷ In the present study, the quantitative evaluation of results showed that the HT is acceptable to children, and it is preferred over standard filling techniques, due to the ease of application and overall patient comfort as a young patient do not have to undergo traumatic injections.

Hall technique is much more accepted by the children and must be used by the dentist as their first option whenever indications to the treatment is fulfilled, as a level of pain or discomfort is lower with this technique than with the conventional techniques, according to the result of the study presented. However, it requires judicious case selection, precise diagnosis radiographically, and efficient behavior management. This technique also reduces the risk of further caries development by full crown coverage.¹²

CONCLUSION

In general, the Hall technique is established to be a better technique in comparison to conventional technique for restoring carious primary molars in terms of effectiveness and acceptability in children age 6–10 years. According to the results obtained, the following conclusion can be drawn:

- The OVDs measured at different interval of time shows that after the placement of SS crowns the OVD increases but within 3–4 weeks the value of OVD came back to the range near to normal. The minimal change in OVD explained the effectiveness of the Hall technique.
- All 84 cases show no change after 6 months when examined clinically as well as radiographically that is no formation of secondary caries, crown perforations, reversible or irreversible pulpitis, or inter-radicular radiolucency and thus making it a successful technique.
- Initially, 50% of the total of 84 children showed discomfort after the placement of metal cap which came down to 36% after 1 week and 5% after 6 months. After the results evaluated, the Hall technique is found to be very well accepted by the patient.

The HT has made a huge difference to children, parents, and clinicians in the management of caries in the primary dentition. However, the technique offers a method of managing the early to moderately advanced active dentinal lesion in primary molars, with good evidence of effectiveness, and acceptability to children and parents. This evidence aligns with the positive findings of other studies of biological strategies for managing caries in primary teeth.

REFERENCES

1. Moses J, Rangeeth BN, Gurunathan D. Prevalence of dental caries, socio-economic status and treatment needs among 5 to 15 year old school going children of Chidambaram. *J Clin Diagn Res* 2011;5(1): 146–151.
2. Ludwig KH, Fontana M, Vinson LA, et al. The success of stainless steel crowns placed with the hall technique: a retrospective study. *J Am Dent Assoc* 2014;145(12):1248–1253. DOI: 10.14219/jada.2014.89.
3. Verde AV, Ramos MM, Stoneham AM. Benefits in cost and reduced discomfort of new techniques of minimally invasive cavity treatment. *J Dent Res* 2009;88(4):297–299. DOI: 10.1177/0022034509334157.
4. Chadwick BL, Evans DJ. Restoration of class II cavities in primary molar teeth with conventional and resin modified glass ionomer cements: a systematic review of the literature. *Eur Arch Paediatr Dent* 2007;8(1):14–21. DOI: 10.1007/BF03262565.
5. Innes NP, Stirrups DR, Evans DJ, et al. A novel technique using preformed metal crowns for managing carious primary molars in general practice—a retrospective analysis. *Br Dent J* 2006;200(8): 451–454. DOI: 10.1038/sj.bdj.4813466.
6. Van der Zee V, Van Amerongen WE. Short communication: influence of preformed metal crowns (Hall technique) on the occlusal vertical dimension in the primary dentition. *Eur Arch Paediatr Dent* 2010;11(5):225–227. DOI: 10.1007/BF03262751.
7. Innes N, Evans D, Stewart M, et al. The hall technique: a minimal intervention, child centered approach to managing the carious primary molar A Users Manual, Version 4; 2015.
8. Kaur R, Jindal R, Dua R, et al. Comparative evaluation of the effectiveness of audio and audiovisual distraction aids in the management of anxious pediatric dental patients. *J Indian Soc Pedod Prev Dent* 2015;33(3):192–203. DOI: 10.4103/0970-4388.160357.
9. Topaloglu-Ak A, Eden E, Frencken JE. Perceived dental anxiety among school children treated through three caries removal approaches. *J Appl Oral Sci* 2007;15(3):235–240. DOI: 10.1590/S1678-77572007000300015.
10. Hussein I. The hall technique: the novel method in restoring the carious primary molar that is challenging old concepts. A new tool in the general dentist's toolbox. *Dental Tribune Middle East & Afr* 2015; 18–20.
11. Santamaria RM, Pawlowitz L, Schmoeckel J, et al. Use of stainless steel crowns to restore primary molars in Germany: questionnaire-based cross-sectional analysis. *Int J Paediatr Dent* 2018;28(6):587–594. DOI: 10.1111/ipd.12415.
12. Santamaria RM, Innes N. Sealing carious tissue in primary teeth using crowns: the hall technique. In: *Caries excavation: evolution of treating cavitated carious lesions*, vol. 27. Karger Publishers; 2018. pp. 113–123.
13. Santamaria RM, Innes NP, Machiulskiene V, et al. Alternative caries management options for primary molars: 2.5-year outcomes of a randomized clinical trial. *Caries Res* 2017;51(6):605–614. DOI: 10.1159/000477855.
14. Innes NP, Evans DJ, Stirrups DR. The hall technique; a randomized controlled clinical trial of a novel method of managing carious primary molars in general dental practice: acceptability of the technique and outcomes at 23 months. *BMC Oral Health* 2007;7(1):18. DOI: 10.1186/1472-6831-7-18.
15. Clark W, Geneser M, Owais A, et al. Success rates of hall technique crowns in primary molars: a retrospective pilot study. *Gen Dent* 2017;65(5):32–35.
16. Page LA, Boyd DH, Davidson SE, et al. Acceptability of the hall technique to parents and children. *N Z Dent J* 2014;110(1):12–27.
17. BaniHani A, Deery C, Toumba J, et al. Effectiveness, costs and patient acceptance of a conventional and a biological treatment approach for carious primary teeth in children. *Caries Res* 2019;53:65–75. DOI: 10.1159/000487201.