

Knowledge and Awareness among General Dental Practitioners in Chennai Regarding Rehabilitation with Full Coverage Restoration in Children

Aroonika S Bedre¹, Deepa Gurunathan²

ABSTRACT

Introduction: The endodontic treatment of primary teeth does provide symptomatic relief and masticatory rehabilitation to the child, but mere completion of endodontic procedure does not guarantee long-term success. Teeth that have not been restored coronally after endodontic treatment have high chances of failure.

Aim: The aim of this study was to evaluate the knowledge and awareness among general dental practitioners in Chennai regarding rehabilitation with full coverage restoration in children following pulp therapy.

Materials and methods: A multiple choice questionnaire comprising 15 questions was given to 150 general dental practitioners in Chennai. The questionnaire assessed their knowledge and clinical practice of pulp therapy, tooth preparation, and restorative crowns for pediatric patients. The data were collected and statistically analyzed.

Results: The findings of this study reveal wide variations in the knowledge and practice of general dental practitioners in Chennai regarding rehabilitation with full coverage restoration in children.

Conclusion: The conclusion drawn from this study is that we need to update their knowledge regarding rehabilitation with full coverage restorations in children.

Keywords: Full coverage restorations, Knowledge, Pedodontics, Stainless steel crowns, Strip crowns.

International Journal of Clinical Pediatric Dentistry (2019): 10.5005/jp-journals-10005-1674

INTRODUCTION

As general practitioners form a major component of dental practitioners in the urban and rural population, their knowledge and awareness regarding rehabilitation of primary teeth remain unexplored areas. The endodontic treatment of primary teeth does provide symptomatic relief and masticatory rehabilitation to the child, but mere completion of endodontic procedure does not guarantee long-term success of the tooth. It has been proved in many studies that teeth that have not been restored coronally after endodontic treatment have six times more chances of failure.¹ The concept of full coverage restoration following an endodontic procedure in the case of permanent teeth is well established and well promoted by dental practitioners. However, the essence and necessity of full coverage restorations in post-endodontic primary teeth is still lagging.² The goal of endodontic therapy, especially in primary teeth, is to maintain the stability of teeth and improve aesthetics and function. According to Morgano et al., the strength of endodontically treated teeth corresponds to the remaining dentin. Since the dentinal strength is lowered in endodontically treated primary teeth, it is mandatory to use full coverage restorations in order to have better long-term prognosis.³ Root-filled teeth should always be restored properly as their clinical success depends on the final restorations rather than the endodontic treatment.⁴

The indications of full coronal restoration of primary teeth are: caries on multiple surfaces; involvement of the incisal edge of anterior teeth; extensive cervical decalcification; pulpal therapy; minor caries, but very poor oral hygiene (high-risk patients); disruptive behavior of child which makes placing class III restorations difficult; developmental defects, such as amelogenesis imperfecta;

^{1,2}Department of Pedodontics, Saveetha Dental College, Saveetha Institute of Medical and Technical Sciences, Saveetha University, Chennai, Tamil Nadu, India

Corresponding Author: Deepa Gurunathan, Department of Pedodontics, Saveetha Dental College, Saveetha Institute of Medical and Technical Sciences, Saveetha University, Chennai, Tamil Nadu, India, Phone: +91 9994619386, e-mail: drgdeepa@yahoo.co.in

How to cite this article: Bedre AS, Gurunathan D. Knowledge and Awareness among General Dental Practitioners in Chennai Regarding Rehabilitation with Full Coverage Restoration in Children. *Int J Clin Pediatr Dent* 2019;12(6):590–594.

Source of support: Nil

Conflict of interest: None

fractured teeth; teeth used as space maintainer abutments; or teeth having extensive wear.⁵ Patients with early childhood caries are more susceptible to developing new and recurrent caries. For example, it has been demonstrated that children who were treated under general anesthesia and who were likely to have high levels of disease showed significantly higher subsequent caries rates than a control group who were initially caries-free.⁶

Historically speaking, the two types of crowns that are available for restoring primary teeth are metal and aesthetic crowns. The oldest type is the preformed metal crown (PMC), also known as a stainless steel crown, ion crown, metal crown, and faced-metal crown. It was first introduced by Humphrey in the year 1950. Although myriads of crowns have been used to restore primary teeth, PMC have been considered the ideal restoration for primary molars and the technique is widely taught internationally.^{7–9}

Despite the widespread recommendation of the use of PMC, there is literature which does not support their use, especially by general dental practitioners.¹⁰ This is unfortunate as the literature on PMC is vast. In a study by Roshan et al., stainless steel crowns were reportedly used sometimes or always by only 8% of respondents. It is surprising that many clinicians are not prepared to use them, especially when it is cost-effective to restore a tooth only once.¹¹ The use was low in both the Yorkshire (8%) and Dutch (5%) studies, despite its high success rate in children compared multisurface amalgam restorations.^{12,13} According to a study by Threlfall et al., most of the general dental practitioners (71%) had heard of British Society of Paediatric Dentistry (BSPD) guidelines, but this knowledge had little or no impact on clinical practice. Only 17% of them that had heard of the guidelines had used a stainless steel crown to restore a primary molar in general practice. One explanation could be that they did not believe the scientific evidence supporting the guidelines. They gave personal and practical reasons for not using stainless steel crowns; many believed they were unnecessarily durable for the primary dentition, not aesthetically acceptable, and that children could not tolerate the procedure. Also, many felt that fitting stainless steel crowns was bad use of their time, as they took too long to fit and were impractical in a busy practice. Some felt they had not received sufficient training while others believed the fee structure to be inadequate. Ultimately, the majority of the dentists believed that their traditional treatment for extensively decayed primary molars with glass ionomer was quicker, clinically acceptable, and more tolerable to their patients.¹⁰

Owing to parental criticism of the esthetics of PMC, attempts have been made to develop alternatives approaches. These include fitting a PMC and then cutting a window and bonding a composite facing,¹⁴ or laboratory-bonded composite to the metal. Current research has seen the production of crowns made entirely of plastic materials. The conclusion of Randall¹⁵ was that overall PMC demonstrated greater prognosis and lesser treatment time in comparison with amalgam restorations. The use of composite strip crowns to restore primary anterior teeth is popular in some countries, since better aesthetics can be achieved with this.¹⁶ Resin-bonded composite strip crowns are the first choice restoration for many dentists, mainly because of the superior aesthetics and the ease of repair if the crown subsequently chips or fractures. However, it is the most technique-sensitive option. Moisture contamination with blood or saliva may interfere with the bonding, and bleeding can hamper the shade of the material. Also, adequate tooth structure must remain after caries removal to ensure that there is sufficient surface area for bonding.^{17,18} The aim of this study was to evaluate the knowledge and awareness among parents and general dental practitioners in Chennai regarding rehabilitation with full coverage restoration in children.

MATERIALS AND METHODS

A cross-sectional survey was conducted among general dental practitioners in Chennai in December 2017 after receiving approval from the Review Board of Saveetha Dental College. The study included a random convenience sample comprising 150 participants. The survey instrument was a structured, self-administered multiple choice questionnaire which was developed in consultation with a pedodontist and an endodontist to improve its content validity. It comprised of 15 questions in total, regarding knowledge and clinical practice of pulp therapy, tooth preparation, and restorative crowns for pediatric patients. All the questionnaires were then compiled and statistically analyzed using Statistical Package for Social Sciences (SPSS) software.

RESULTS

57.1% of our study participants were females while 42.9% were males. 42.9% of them treat 1–5 pediatric patients monthly, 32.1% treat 1–5 children daily, and 25% of them treat 1–5 kids weekly.

When asked whether they call pediatric consultants/refer children to pedodontists, 35.7% of them said they often do so, while another 35.7% said they never do so and 28.6% said they rarely do so.

89% of the study participants said that pulp therapy is the best treatment for pulpal involvement (trauma/caries) in primary teeth, while 10.7% of them said extraction (Fig. 1).

60.7% of the dentists agreed that it is mandatory to restore primary teeth with crowns after pulpal treatment whereas, 39.3% of them said that it is not necessary if the remaining tooth structure is sound enough (Fig. 2).

When we asked our study participants about when they would advise restorations of a primary tooth with a crown, 46.4% of the people said that they would do so if it is expected to exfoliate more than a year later, while the others gave varied answers such as 1 year, 6 months, and 3 months before the tooth is expected to exfoliate (Fig. 3).

When asked about why crowns are not so frequently used in primary teeth, 28.6% of the dentists said that it is because of patient’s lack of knowledge, while 25% claimed it to be due to patient’s unaffordability and another 25% of them said because of patient’s disinterest. While 17% of them felt that the reason was dentist’s lack of knowledge, a minor 3.5% of them felt that it was time consuming (Fig. 4).

When asked if crowns can be placed under general anesthesia, 78.6% agreed, while 17.9% were unsure and 3.6% disagreed.

Majority of the dentists (60.7%) preferred composite strip crowns (celluloid crowns) as the ideal choice of full coronal restoration for primary anterior teeth. 21.4% of the dentists chose polycarbonate crowns, and 10.7% opted for stainless steel crowns (Fig. 5).

35.7% of the participants said that 0.5 mm of occlusal reduction is required for stainless steel crowns, whereas 32.3% of them said, 1.5–2 mm and 32.1% of them said, 1 mm (Fig. 6).

When asked about which surface requires the least amount of reduction for stainless steel crown, 42.9% of the dentists agreed that it is the lingual surface, while 28.6% of them said buccal, 25% of them said occlusal, and 3.5% said distal (Fig. 7).

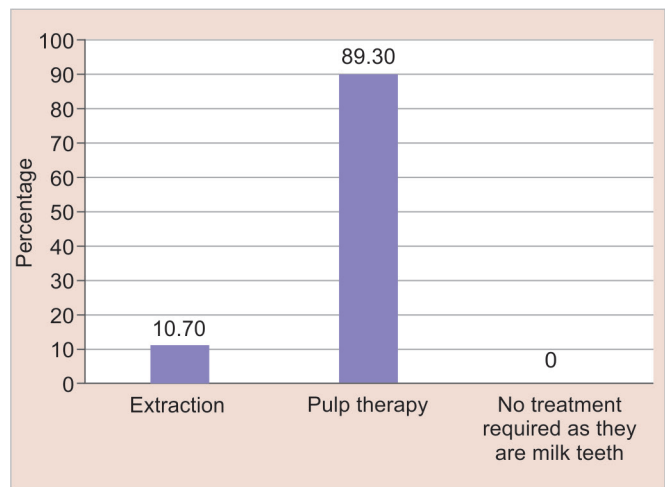


Fig. 1: Best treatment for pulpal involvement (trauma/caries) in primary teeth

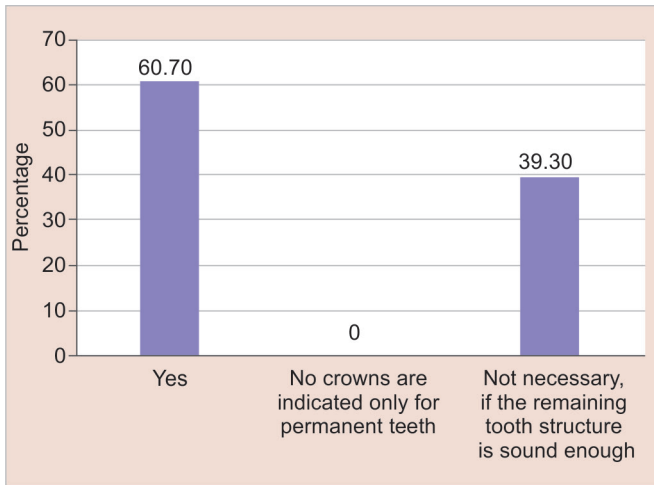


Fig. 2: Whether it is mandatory to restore primary teeth with crowns after pulpal treatment

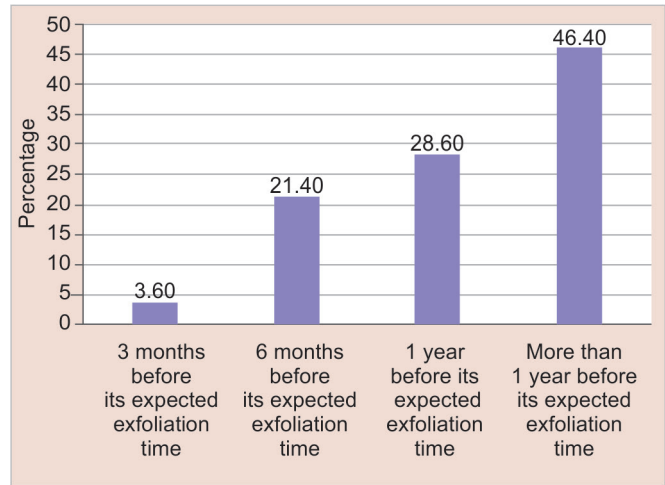


Fig. 3: When restoration of a primary tooth with a crown is advised

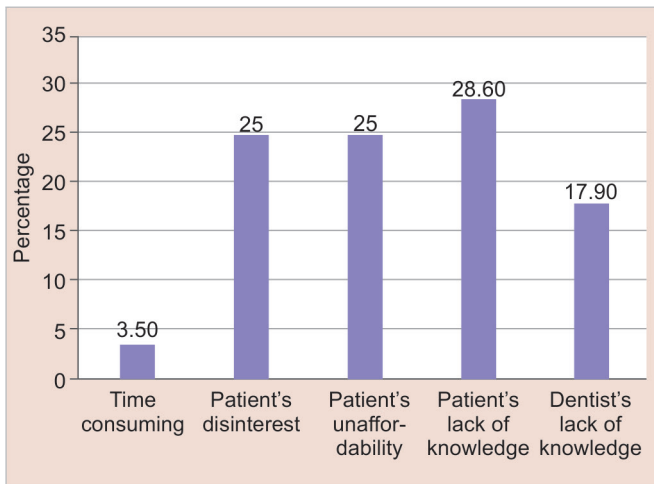


Fig. 4: Why crowns are not so frequently used in primary teeth

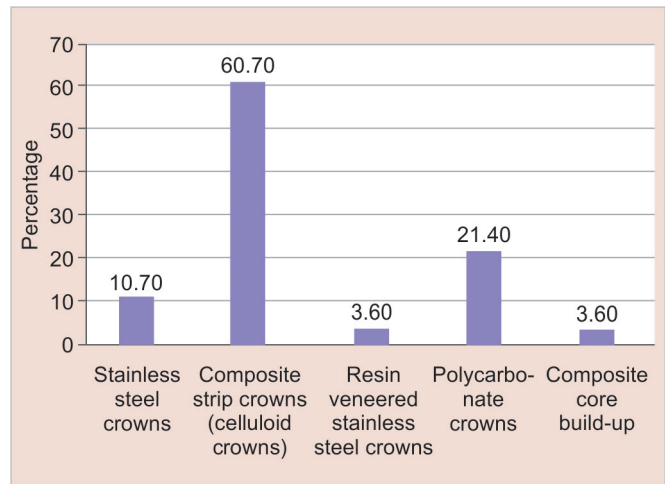


Fig. 5: Ideal choice of full coronal restoration for primary anterior teeth

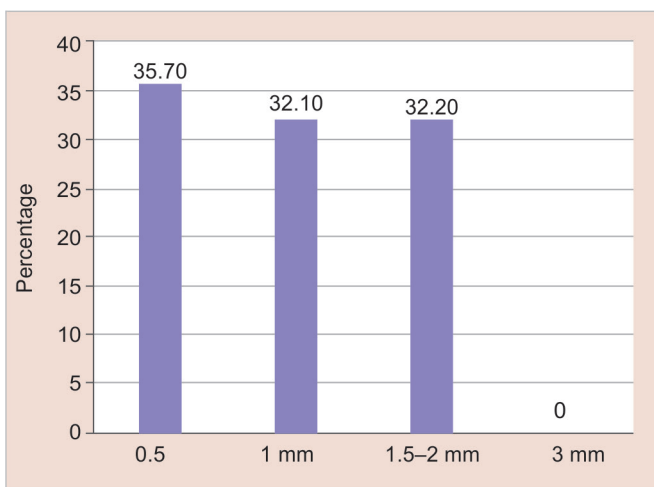


Fig. 6: Amount of occlusal reduction required for stainless steel crowns

35.7% of the people said that the crown margin on the buccal surface of the primary molar is like a stretched out, while 32.1% said it is smile like, 25% said it is flat, and 7.1% said it is frown like.

92.9% of the dentists use glass ionomer cement to lute stainless steel crowns while 7.1% use zinc phosphate.

We asked our study participants if crowns should be placed in infraocclusion to prevent trauma. 46.4% of them disagreed to the statement, while 25% of them agreed and 28.6% remained unsure (Fig. 8).

DISCUSSION

Restoration with crowns is necessary following endodontic treatment of teeth. Our study aimed at evaluating the knowledge and awareness among parents and general dental practitioners regarding rehabilitation with full coverage restoration in children. Majority of the study participants said that pulp therapy is the best treatment for pulpal involvement (trauma/caries) in primary teeth, while few of them said extraction. According to a study by Aman Moda et al., 40% of the general dentists felt that the best treatment in case of primary necrotic teeth is extraction.² Hussain et al. also evaluated the same in their study.¹⁹

Many dentists agreed that it is mandatory to restore primary teeth with crowns after pulpal treatment, whereas others said that it is not necessary if the remaining tooth structure is sound enough.

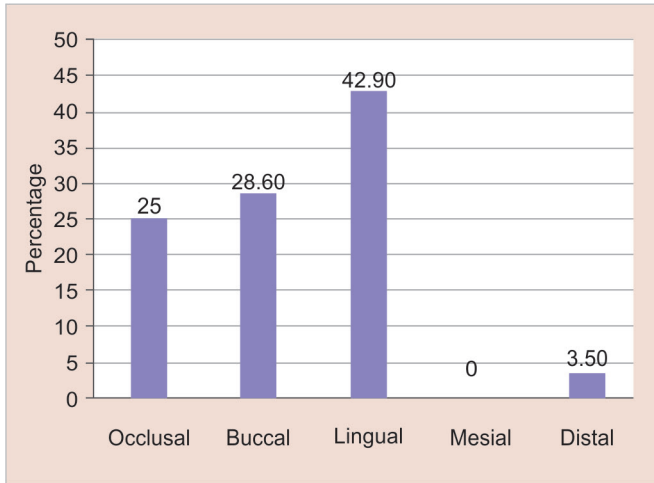


Fig. 7: Surface that requires the least amount of reduction for stainless steel crown

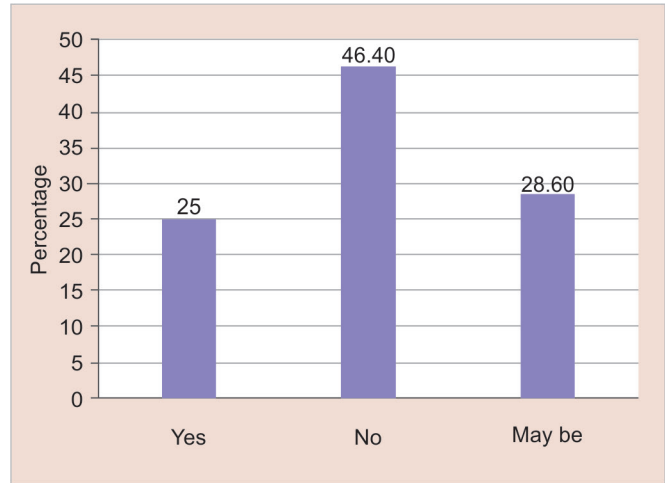


Fig. 8: Whether crowns should be placed in infraocclusion to prevent trauma

In a study by Aman Moda et al., only 33% of the general dental practitioners realized the importance of full coverage restoration after primary pulp therapy out of which only 13% knew about stainless steel crowns. Most of the practitioners who answered these were of relatively younger generation. The main reason for this could be the inclusion of such advancements in the recent undergraduate curriculum.² Mcknight-Hanes et al. compared the treatment recommendations for the primary teeth and concluded that more general dental practitioners recommended restorations whereas pediatric dentists recommended the use of stainless steel crowns followed by pulp therapy.²⁰

When asked about why crowns are not so frequently used in primary teeth, most of the dentists said that it is because of patient's lack of knowledge, and minority of them felt that it was time consuming. In a study by Moda, 62% of general dental practitioners pointed out patient's noninterest in providing crowns whereas cost and lack of knowledge were the secondary reasons.²

The various anterior crowns available for restoring primary anterior teeth are preveneered stainless steel crowns, polycarbonate crowns, pedo pearls, strip crowns, facial cut-out stainless steel crowns, pedo jacket crowns, zirconia crowns, new millennium crowns, art glass crowns.¹⁸ Among crowns celluloid crowns are a popular method of restoring primary anterior teeth. These crowns provide superior aesthetics than other forms of anterior coronal coverage restorations. If these crowns are chipped or fractured, repair is possible.²¹ Majority of the dentists (60.7%) preferred composite strip crowns (celluloid crowns) as the ideal choice of full coronal restoration for primary anterior teeth. 21.4% of the dentists chose polycarbonate crowns, and 10.7% opted for stainless steel crowns. According to a study by Roshan et al., only 4% of respondents use strip crowns, although a very useful means in the reconstruction of severely carious or hypoplastic anterior primary teeth.^{7,11} This is especially so when the mesiodistal walls of teeth are affected as in cases of nursing bottle syndrome and less frequently traumatic injuries. However, it must be noted that due to parents' reluctance in restoring primary teeth, and anterior teeth perceived as less important than posterior teeth, many are simply extracted. This is a pity as the aesthetic restoration of primary incisors can be beneficial to a young child's self-confidence.¹¹

Nash stated that 69l or 169l bur is used to reduce the occlusal surface by 1.5–2 mm following the cuspal outline and maintaining the original contour of the cusp. Humphrey (1950) stated that occlusal reduction is necessary to preserve as much tooth structure as possible. Rapp said that occlusal surface should be reduced such that 4 mm of tooth structure is available from gingival margin. According to Mink and Bennet, 1–1.5-mm tooth reduction is required. Troutman stated that 1-mm tooth reduction is necessary. Kennedy said that 1.5–2 mm of tooth reduction needs to be done.²¹ In our study, most of the participants said that 0.5 mm of occlusal reduction is required for stainless steel crowns.

Buccolingual reduction for stainless steel crown preparation is often limited to the bevelling of the bucco-occlusal and occluso-gingival line angles and is confined to the occlusal one-third of the crown. The (unprepared) prominence on the lingual surface helps in retention of the stainless steel crown.²¹ In our study, when asked about which surface requires the least amount of reduction for stainless steel crown, majority of the dentists agreed that it is the lingual surface. Because of the mesiobuccal cervical bulge of the first primary molar, the buccal gingival margin dips down as it is traced from distal to mesial which resembles a stretched S.²¹ In our study, most of the participants agreed to this statement (Fig. 8). Small sample size and evaluation of participants in a single city alone are the limitations of our study.

CONCLUSION

The general practitioners showed wide variations in their knowledge and practice. While most of them seemed to have a good amount of knowledge, dilemmatic attitudes were noted regarding the necessity of crowns and tooth reduction. The conclusion drawn from this study is that we need to update their knowledge regarding rehabilitation with full coverage restorations in children.

REFERENCES

1. Salehrabi R, Rotstein I. Endodontic treatment outcome in a large patient population in USA: an epidemiological study. *J Endod* 2004 Dec;30(12):846–850. DOI: 10.1097/01.don.0000145031.04236.ca.
2. Moda A, Saroj G, et al. Knowledge and awareness among parents and general dental practitioners regarding rehabilitation with full

- coverage restoration in children: a multi-centric trial. *Int J Clin Pediatr Dent* 2016;9(2):177–180. DOI: 10.5005/jp-journals-10005-1359.
3. Morgano SM, Rodrigues AH, et al. Restoration of endodontically treated teeth. *Dent Clin North Am* 2004 Apr;48(2):397–416. DOI: 10.1016/j.cden.2003.12.011.
 4. Safavi KE, Dowden WE, et al. Influence of delayed coronal permanent restoration on endodontic prognosis. *Endod Dent Traumatol* 1987 Aug;3(4):187–191. DOI: 10.1111/j.1600-9657.1987.tb00622.x.
 5. Waggoner WF. Restorative dentistry for the primary dentition. Pinkham JR. *Pediatric dentistry: infancy through adolescence*, 2nd ed., Philadelphia, PA: W. B. Saunders; 1994. pp. 298–325.
 6. Almeida AG, Roseman M, et al. Future caries susceptibility in children with early childhood caries following treatment under general anesthesia. *Pediatr Dent* 2000;22:302–306.
 7. Duggal MS, Curzon MEJ, et al. Restorative techniques in paediatric dentistry. London: Martin Dunitz Ltd; 1995.
 8. McDonald RE, Dean JE, et al. *Dentistry for the child and adolescent*, 8th ed., St. Louis, MO: Mosby; 2004.
 9. Welbury R, Duggal MS, et al. *Paediatric dentistry*, 3rd ed., Oxford University Press; 2005.
 10. Threfall AG, Pilkington L, et al. General practitioners' views on the use of stainless steel crowns to restore primary molars. *Br Dent J* 2005;199:453–455. DOI: 10.1038/sj.bdj.4812746.
 11. Roshan D, Curzon ME, et al. Changes in dentists' attitudes and practice in paediatric dentistry. *Eur J Paediatr Dent* 2003 Mar;4(1):21–27.
 12. Roberts JF, Sherriff M. The fate and survival of amalgam and preformed crown molar restorations placed in a specialist paediatric dental practice. *Br Dent J* 1990 Oct 20;169(8):237–244. DOI: 10.1038/sj.bdj.4807333.
 13. Papathanasiou AG, Curzon ME, et al. The influence of restorative material on the survival rate of restorations in Primary molars. *Pediatr Dent* 1994 Jul–Aug;16(4):282–288.
 14. Roberts JF. The open-face stainless steel crown for primary molars. *J Dent Child* 1983;50:262–263.
 15. Randall RC. Preformed metal crowns for primary and permanent teeth: review of the literature. *Pediatr Dent* 2002;24:489–500.
 16. Lee JK. Restoration of primary anterior teeth: review of the literature. *Pediatr Dent* 2002;24:506–511.
 17. Waggoner WF. Restoring primary anterior teeth. *Pediatr Dent* 2002;24:511–516.
 18. Srinath S, Kanthaswamy AC. *J Pharm Sci Res* 2017;9(2):190–193.
 19. Hussain AS, Abu-Hassan MI, et al. Parent's perception on the importance of their children's first dental visit (a cross-sectional pilot study in Malaysia). *J Oral Res Hussein Jor* 2013;1(1):17–25.
 20. Mcknight-Hanes C, Myers DR, et al. A comparison of general dentist's treatment recommendations for primary teeth. *Pediatr Dent* 1991 Nov–Dec;13(6):344–348.
 21. Muthu MS. *Multiple choice questions in paediatric dentistry*, 1st ed., New Delhi: Elsevier; 2005. p. 187.