

Rugoscopy as a Gender Determination Tool and its Appositeness in Malocclusion among Adolescents Aged 13–18 Years

Dandamudi Lalithya¹, Ila Srinivasan², Jyothsna V Setty³, Sunaina Pamnani⁴, Murali K Dindukurthi⁵, Sindura Allani⁶

ABSTRACT

Aim: The aim of the study was to determine the relationship between malocclusion and palatal rugae patterns and its reliability in gender determination of adolescents aged 13–18 years.

Materials and methods: A total of 90 children with 30 in each of skeletal class I, II and III groups respectively were included in the study. The lateral cephalograms of the study samples were analyzed cephalometrically using ANB angle, WITS appraisal and beta angle and categorized as skeletal class I, class II or class III sagittal skeletal jaw relation. Sassouni's Archial analysis was used to reconfirm skeletal jaw relation and also to assess treatment needs. Palatal rugae of each sample were recorded to study the patterns. Thomas and Kotze classification was followed for rugae pattern analysis.

Results: No definite rugae print pattern could be associated with any particular sagittal skeletal jaw relation in the present study. Female population of class II skeletal malocclusion showed a significant difference for number of rugae on the right and left sides of mid palatine raphe. Discriminant function analysis showed no significance when the number of rugae were compared among males and females for gender determination.

Conclusion: As rugoscopy was neither found to provide absolute conclusive evidence in identification of any particular jaw relationship nor gender determination, combination with more reliable forensic methods would help in better personal identification.

Clinical significance: Palatal rugae and craniofacial skeleton develop at the same embryonic period. Developmental factors that cause malocclusions should also reflect in the palatal rugae patterns. There exists a deficiency in studies in samples of younger age group and hence the need of the study.

Keywords: Palatal rugae, Rugoscopy, Sagittal skeletal jaw relation, Skeletal malocclusion.

International Journal of Clinical Pediatric Dentistry (2019): 10.5005/jp-journals-10005-1642

INTRODUCTION

The cornerstone of forensic science is the positive identification of living or deceased using unique traits and characteristics of the person. Identity of a person does not end at his finger, palm, or foot prints but also includes his distinct dental features from a forensic point of view. It is a well-established fact that rugae retains its shape throughout life and resists decomposition. Personal identification is based on the rugae pattern since the palate would remain intact when most other anatomical structures are destroyed, burnt, or dehydrated and also in situations where there are no finger prints. Thus, in forensic dentistry, the unique characteristic pattern of palatal rugae can be used as an identification tool.¹

Palatal rugae were first described by Winslow in 1732. The earliest illustration of palatal rugae was probably made by Santorini in 1775, wherein he put a drawing depicting three wavy lines crossing the midline of palate. The first palatal classification system was put forth by Gorla in 1911. The first suggestion for the use of palatal rugae as a method of personal identification was suggested by Harrison Allen in 1889. The term "palatal rugoscopy" was proposed in 1932, by a Spanish investigator named Trobo Hermosa.²

Palatal rugae or transverse palatine folds are asymmetrical and irregular elevations of the mucosa in anterior third of the palate in the midsagittal plane, arranged in a transverse direction on each side of the median palatal raphae and behind the incisive papilla. They are also called "plica palatinae" or "rugae palatine."^{3,4}

The pattern of orientation is formed by 12th–14th weeks of intrauterine life from the hard connective tissue covering the palatal

^{1–6}Department of Pedodontics and Preventive Dentistry, Dr Mathrushri Ramabai Ambedkar Dental College and Hospital, Bengaluru, Karnataka, India

Corresponding Author: Dandamudi Lalithya, Department of Pedodontics and Preventive Dentistry, Dr Mathrushri Ramabai Ambedkar Dental College and Hospital, Bengaluru, Karnataka, India, Phone: +91 7019849795, e-mail: lalithyadandamudi@gmail.com

How to cite this article: Lalithya D, Srinivasan I, *et al.* Rugoscopy as a Gender Determination Tool and its Appositeness in Malocclusion among Adolescents Aged 13–18 Years. *Int J Clin Pediatr Dent* 2019;12(4): 307–311.

Source of support: Nil

Conflict of interest: None

bone, and their formation is under genetic control and remain stable until the oral mucosa degenerates after death.^{5,6}

Mixed dentition period is the time of greatest opportunity for occlusal guidance and interception of malocclusion. At this time, the dentist has the greatest challenges and finest opportunities for efficient orthodontic therapy.

It is stated that fingers, palms, lips, alveolus, and palate develop during the same embryonic period.⁷ A correlation between thumb prints and sagittal dental malocclusion has been established through research.⁸ Similarly, rugoscopy has also been used to determine malocclusion in adult populations^{9,10} but there is a scarcity in literature comparing all three skeletal malocclusions and palatal rugae in children and young adolescents and hence

the study is intended to determine various predominant patterns found in different classes of skeletal malocclusion as well as the reliability of rugoscopy in gender determination.

MATERIALS AND METHODS

It is an observational, hospital-based study. A convenience sample of 90 adolescents in the age group of 13–18 years, with 30 in each skeletal malocclusion and with equal gender distribution were selected from patients visiting the Department of Pedodontics and Preventive Dentistry and Department of Orthodontics, Dr Mathrushri Ramabai Ambedkar Dental College and Hospital, Bengaluru. Lateral cephalograms of all the selected subjects were taken in natural head position (NHP) with the help of X-ray system in the institution (KODAK 8000 C Digital cephalometric system). ANB angle, WITS appraisal, and Beta angle were calculated for each cephalogram to assess the anteroposterior jaw position. Keeping the norms into consideration, they were categorized into class I, class II, and class III skeletal jaw relation groups when at least two norms coincided. All cephalometric analyses were performed by one individual to prevent any interobserver bias.

The palatal rugae patterns of each sample under class I, class II, and class III groups were recorded. An irreversible hydrocolloid was used as an impression material on an appropriate perforated metal tray for the maxillary dental arch for all subjects. The impressions were then poured with type III dental stone and base with plaster following all instructions by the manufacturer. Utmost care was taken to prevent voids or air bubbles, and all the casts were preserved for interpretation.

The rugae were delineated using a sharp graphite pencil (0.3 HB) under adequate light and magnification, and analyzed according to the classification given by Thomas and Kotze, which include the number, length, shape, direction, and unification of rugae.¹¹ All palatal rugae analyses were done by an observer who was blinded in relation to clinical examination and cephalometric analysis of the patient.

Statistical Package for Social Sciences (SPSS) for Windows, Version 22.0. Released 2013. Armonk, NY: IBM Corp., was used to perform statistical analyses.

A Chi-square test was used to compare the palatal rugae patterns between different skeletal malocclusions. Similarly, gender-based comparisons were done for different skeletal malocclusions.

An independent student’s *t* test was used to conduct a gender-wise comparison of mean number of rugae in the right and left

sides of mid-palatine raphe in different skeletal malocclusions and also in the overall samples. Student’s paired *t* test was used to determine the mean number of rugae between right and left sides of mid-palatine raphe among male and female subjects in different skeletal malocclusions.

A discriminant function analysis was done for the number of rugae on the right and left sides of mid-palatine raphe for gender prediction. A *p* value <0.05 was considered to be statistically significant.

RESULTS

Mean age of the samples in class I group was 14.1 ± 1.2 years, in class II was 14.3 ± 1.2 years, and in class III was 13.6 ± 1.0 years (Table 1).

The most prevalent palatal rugae length was found to be primary type (100%) and the predominant rugae shape was wavy followed by curved, straight, and circular patterns in that order. Among the two different directions of rugae, forward (64.4%) was more prevalent and the majority of the population had no unification (43.3%) (Fig. 1).

When all the three skeletal malocclusions were compared, there was no statistically significant difference in the length, shape, direction, and unification of rugae patterns.

The mean number of rugae on the right and left sides of mid-palatine raphe in class II skeletal malocclusion was significantly high (*p* < 0.05) (Table 2).

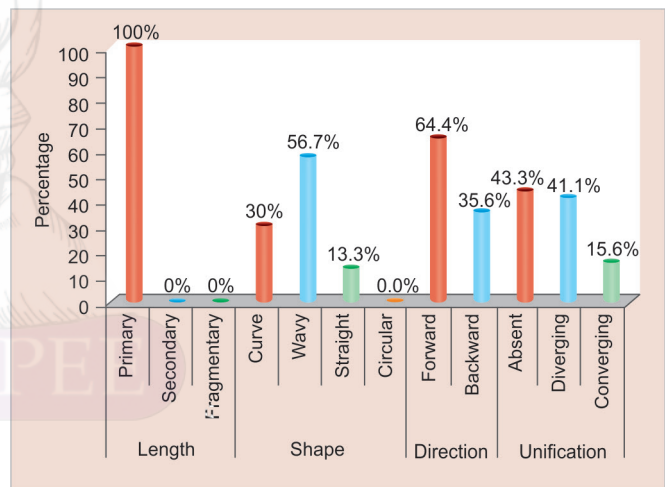


Fig. 1: Distribution of different palatal rugae forms in over-all sample

Table 1: Age and gender distribution among study subjects in different groups

Variables	Categories	Class I		Class II		Class III	
		n	(%)	n	(%)	n	(%)
Gender	Males	15	50.0	15	50.0	15	50.0
	Females	15	50.0	15	50.0	15	50.0
Age	12 years	2	6.7	2	6.7	4	13.3
	13 years	10	33.3	6	20.0	11	36.7
	14 years	4	13.3	7	23.3	9	30.0
	15 years	10	33.3	10	33.3	6	20.0
	16 years	4	13.3	5	16.7	0	0.0
Mean age (in years)	Mean and SD	14.1	1.2	14.3	1.2	13.6	1.0



Table 2: Comparison of mean number of rugae between the right and left sides of mid-palatine raphe in different skeletal malocclusions using Student's paired t test

Group	Sides	N	Mean	SD	SEM	Mean diff	t	p value
Class I	Right	30	4.8	1.3	0.2	-0.36	-1.408	0.17
	Left	30	5.1	1.2	0.2			
Class II	Right	30	4.3	1.0	0.2	-0.83	-3.785	0.001*
	Left	30	5.1	1.3	0.2			
Class III	Right	30	5.0	1.2	0.2	0.13	0.611	0.55
	Left	30	4.9	1.2	0.2			

*Statistically significant

Table 3: Comparison of mean number of rugae between right and left sides of mid-palatine raphe among male and female subjects in different skeletal malocclusions using Student's paired t test

Group	Sex	Sides	N	Mean	SD	SEM	Mean diff	t	p value
Class I	Males	Right	15	4.4	0.9	0.2	-0.7	-1.625	0.13
		Left	15	5.1	1.3	0.3			
	Females	Right	15	5.1	1.5	0.4	-0.1	-0.211	0.84
		Left	15	5.2	1.2	0.3			
Class II	Males	Right	15	4.4	1.2	0.3	-0.5	-1.284	0.22
		Left	15	4.9	1.4	0.4			
	Females	Right	15	4.2	0.7	0.2	-1.2	-5.392	<0.001*
		Left	15	5.4	1.2	0.3			
Class III	Males	Right	15	4.9	1.1	0.3	0.1	0.202	0.84
		Left	15	4.8	0.8	0.2			
	Females	Right	15	5.1	1.3	0.3	0.2	0.676	0.51
		Left	15	4.9	1.5	0.4			

*Statistically significant

Table 4: Discriminant function analysis of mean number of rugae for gender prediction

Variables	Wilks' lambda	F statistic	df1	df2	p value
Right	0.987	1.176	1	88	0.28
Left	0.988	1.081	1	88	0.30

Among the three classes of skeletal malocclusion, the female population of class II had a highly statistically significant number of rugae on the left side of mid palatine raphe than the right side ($p < 0.05$) (Table 3).

A discriminant function analysis for the number of rugae present on the right and left sides of the mid-palatine raphe was conducted (Table 4), but the number of rugae on the right and left sides did not significantly contribute to the discriminant function.

DISCUSSION

Identification of a person plays a very important role in forensic sciences. There are several methods that seek to establish human identity and the importance of dental identification has been increasing lately.

There are several pieces of evidence that relate the palatal rugae patterns to inheritability. Patel et al. found a statistically significant resemblance of rugae patterns among off-springs and their parents and concluded that there is an important role of heredity in palatal rugae patterns.

Extraneous factors that cause malocclusions at the time of development should also reflect in the palatal rugae patterns. Hence, it is hypothesized that hereditary and environmental factors leading to malocclusions may also cause abnormalities in rugae patterns.

The age group of 13–18 years was selected based on the evidence that orientation pattern gets established at birth attaining a final feature during adolescence and thereafter any change that occurs may be in length but not in shape of the rugae.¹²

Various methods have been used to study palatal rugae patterns among which the study of maxillary dental cast is the most commonly used technique.¹³ Limson and Julian compared digitized casts with stored records and the results showed that digitized rugae pattern samples matched the patterns in stone records.¹⁴ Hence the present study chose dental stone casts as they have similar results as digitized records with advantages of simple analysis, minimum fabrication cost, and the possibility of future comparative review, when needed. The evaluation of casts was conducted by a single investigator as complex shapes may generate inter-observer variation in identification.

After a thorough review on all classifications from the literature, the method of identification used in this study is Thomas and Kotze classification, which includes number, length, shape, and unification of rugae. This classification is most commonly followed for recording the rugae patterns.¹¹

The study intended to evaluate the reliability of rugae as a tool in gender determination and hence equal number of males and females were included in each group of the study population.

Studies in the literature have reported that palatal rugae are unique to every individual. In a study done by Viridi et al. in a pediatric population revealed that palatal rugae patterns are unique and do not change over a period of time.¹⁵ Similarly, in the present study, each subject's palatal rugae were found to be unique.

No single parameter in cephalometric analysis should be relied on entirely and interpreted as absolute value.¹⁶ Therefore in the present study ANB angle, WITS appraisal, and β angle were used in combination to diagnose the sagittal skeletal jaw relation.

A study done by Oral et al., reported that wavy type of rugae was the most common pattern in different sagittal skeletal malocclusion groups of Turkish background,¹⁷ which was consistent with the present study. Class II skeletal malocclusion group showed a significant difference for the mean number of rugae on right and left sides of the mid-palatine raphe but no significant difference was noted among the three groups, which is consistent with those reported by Suhartono et al.¹⁸ and Oral et al.¹⁷

Deval et al., in 2016 also found that converging type of rugae pattern was more common in class I and class II malocclusion (54% each) and diverging type in class III malocclusion (48%). This result was in slight contradiction to the present study, which revealed a diverging type of rugae pattern to be predominant in all the three skeletal malocclusion groups and this contrasting result could be attributed to the difference in the ethnicity among the sample populations.¹⁹

Kapali et al. and Saraf et al. did not reveal any significant differences in the number of primary rugae between Aboriginal males and females.^{20,21} The present study also did not show any significant difference in the number of rugae between males and females. These results do not conform to the results presented by Dohke and Osato, who indicated that among the Japanese, females had fewer rugae than males.²² This may be due to the fact that secondary and fragmentary rugae were not included in the present study and it is the secondary rugae that Dohke et al.²² and Ahmed et al.,²³ considered in their study, leading to difference between the sexes.

The findings of the present study indicate that there is no sexual dimorphism in rugae shapes ($p > 0.05$), which concurs with the findings for Jordanians,²⁴ Rwandans,²⁵ Egyptian, and Saudi children²⁶ but contradicts the findings in Saudi adults,²⁷ where converging and circular patterns showed sexual dimorphism. This may suggest that the degree of sexual differences in rugae patterns differs between populations.

These variations among different populations may indicate ethnic variability in the expression of sexual dimorphism using palatal shapes as most of the previous studies among Indians indicated a lack of sexual dimorphism in palatal rugae.²⁸ The findings of the current study (including palatal rugae shapes, directions and unification) did not show this discriminatory ability, which indicates that the palatal rugae cannot be used as an effective tool in the assigning of sex.

CONCLUSION

From this study the following conclusions can be drawn:

- Female population of class II skeletal malocclusion showed a significant difference for the number of rugae on the right and left sides of mid palatine raphe.
- No definite rugae print pattern could be associated with any particular sagittal skeletal jaw relation in the present study.

- Discriminant function analysis showed no significance when the number of rugae were compared among males and females for gender determination.

As rugoscopy was neither found to provide absolute conclusive evidence in identification of any particular jaw relationship nor gender determination, combination with more reliable forensic methods would help in better personal identification.

REFERENCES

1. Ohtani M, Nishida N, et al. Indication and Limitation of using palatal rugae for Personal Identification in Edentulous Cases. *Forensic Sci Int* 2008;176:178–182. DOI: 10.1016/j.forsciint.2007.09.002.
2. Krishnappa S, Srinath S, et al. Palatal Rugoscopy: Implementation in Forensic Odontology-A Review. *J Adv Med Dent Scie* 2013;1(2):53–59.
3. Patil MS, Patil SB, et al. Palatine rugae and their significance in clinical dentistry: a review of the literature. *J Am Dent Assoc* 2008;139:1471–1478. DOI: 10.14219/jada.archive.2008.0072.
4. Sivaraj A. Significance of rugae in orthodontics. *J Orofac Res* 2013;3(3):202–209.
5. Buchtová M, Tichý F, et al. The development of palatal rugae in the European pine vole, *Microtus subterraneus* (Arvicolidae, Rodentia). *Folia Zoo* 2003;52:127–136.
6. Sadler TW. *Langman's Medical Embryology*. Baltimore: Williams and Wilkins; 1990. pp. 316–320.
7. Kanematsu N, Yoshida Y, et al. Study on abnormalities in the appearance of finger and palm prints in children with cleft lip, alveolus, and palate. *J Oral Maxillofac Surg* 1986;14:74–82. DOI: 10.1016/S0301-0503(86)80265-X.
8. Tikare S, Rajesh G, et al. Dermatoglyphics - A marker for malocclusion? *Int Dent J* 2010;60(4):300–304.
9. Kulkarni N, Vasudevan SD, et al. Cheiloscopy: A new role as a marker of sagittal jaw relation. *J Forensic Dent Sci* 2012;4:6–12. DOI: 10.4103/0975-1475.99152.
10. Gandikota C, Venkata YP, et al. Comparative study of palatal rugae pattern in class II div 1 and class I individuals. *J Pharm Bioall Sci* 2012;4:358–363. DOI: 10.4103/0975-7406.100271.
11. Thomas CJ, Kotze TJ. The palatal rugae pattern: a new classification. *J Dent Assoc S Afr* 1983;38(3):153–157.
12. Jordanov JA. Growth of the hard palate in man. *Anthropological characteristics. Z Morphol Anthropol* 1971;63:230–237.
13. Almeida MA, Phillips C, et al. Stability of the palatal rugae as landmarks for analysis of dental casts. *Angle Orthod* 1995;65:43–48.
14. Limson KS, Julian R. Computerized recording of the palatal rugae pattern and an evaluation of its application in forensic identification. *J Forensic Odontostomatol* 2004;22(1):1–4.
15. Viridi M, Singh Y, et al. Role of palatal rugae in forensic identification of the pediatric population. *Internet J Forensic Sci* 2009;4(2):1–6.
16. Baik CY, Ververidou M. A new approach of assessing sagittal discrepancies: The Beta angle. *Am J Orthod Dentofacial Orthop* 2004;126:100–105. DOI: 10.1016/j.ajodo.2003.08.026.
17. Oral E, Kutalm S, et al. Evaluation of palatal rugae pattern in different sagittal skeletal relationship adolescent subjects. *Medicine* 2017;96(14):1–4. DOI: 10.1097/MD.0000000000006440.
18. Suhartono AW, Syafitri K, et al. Palatal rugae patterning in a modern Indonesian population. *Int J Legal Med* 2016;130:881–887. DOI: 10.1007/s00414-015-1272-5.
19. Deval A, Gunjan Y, et al. Palatal rugoscopy and dermatoglyphics: a Marker for malocclusion and its Specificity in sexes? *University J Dent Sci* 2016;2(2):34–40.
20. Kapali S, Townsend G, et al. Palatal rugae patterns in Australian Aborigines and Caucasians. *Aust Dent J* 1997;42:129–133. DOI: 10.1111/j.1834-7819.1997.tb00110.x.
21. Saraf A, Bedia S, et al. Rugae patterns as an adjunct to sex differentiation in forensic identification. *J Forensic Odontostomatol* 2011;29(1):14–19.

22. Dohke M, Osato S. Morphological study of the palatal rugae in Japanese 1. Bilateral differences in the regressive evaluation of the palatal rugae. *Jap J Oral Biol* 1994;36:125–140. DOI: 10.2330/joralbiosci1965.36.126.
23. Ahmed AA, Hamid A. Morphological Study of Palatal Rugae in a Sudanese Population. *Int J Dent* 2015; 1–8. DOI: 10.1155/2015/650648.
24. Mustafa AG, Allouh M, et al. Morphometric analysis of palatal rugae among Jordanians: further evidence of worldwide palatal rugae individuality. *Aust J Forensic Sci* 2014;46(1):53–63. DOI: 10.1080/00450618.2013.804947.
25. Goyal S, Goyal S. Study of palatal rugae pattern of Rwandan patients attending the dental department at King Faisal hospital, Kigali, Rwanda: a preliminary study. *Rwanda Med J* 2013;70(1):19–25.
26. Fahmi FM, Al-Shamrani SM, et al. Rugae pattern in a Saudi population sample of males and females. *Saudi Dent J* 2001;13(2):92–95.
27. Kallianpur S, Desai A, et al. An anthropometric analysis of facial height, arch length, and palatal rugae in the Indian and Nepalese population. *J Forensic Dent Sci* 2011;3(3):33–37. DOI: 10.4103/0975-1475.85294.
28. Kumar S, Vezhavandhan, et al. Palatal rugoscopy among Puducherry population. *J Contemp Dent Pract* 2012;13(3):401–404. DOI: 10.5005/jp-journals-10024-1158.

