

# Primary Canine and Molar Relationships in Centric Occlusion in 3- to 6-year-old Children: A Cross-sectional Survey

Dilip Kumar<sup>1</sup>, Deepa Gurunathan<sup>2</sup>

## ABSTRACT

**Introduction:** The occlusal relationship of primary dentition plays a vital role in predicting malocclusion in permanent dentition because primary dentition is the stepping stone for permanent dentition.

**Aim:** The aim of the study was to assess the occlusal relationships between the primary canine and the primary molar in the primary dentition in centric occlusion and also spacing in primary dentition among a group of 3- to 6-year-old children.

**Materials and methods:** The survey was based on examination of the primary dentition of 100 school children aged 3–6 years from Chennai, Tamil Nadu, India. The examination was done using pen light and mouth mirror. The occlusal assessment was done only on children who are healthy and free from extensive caries. The primary molar relationship and the canine relationship were assessed using Foster and Hamilton criteria with the teeth in centric occlusion.

**Results:** The study showed that, out of 100 school children, the molar relationship 56% had mesial step followed by 36% with flush terminal relationship and 8% with distal step relationship and out of 100 children, the canine relationship 61% of children had class III relationship followed by 27% class I relationship and 12% class II relationship. And around 54% had spacing out of which, maximum spacing was found only in the upper anteriors.

**Conclusion:** The survey concluded showing that the mesial step primary relationship was more common among 5- to 6-year-old children followed by flush terminal relationship and distal step relationship. The class III primary canine relationship was more common followed by classes I and II. Spacing was found more common in upper anteriors.

**Keywords:** Centric relation, Primary dentition, Spacing.

*International Journal of Clinical Pediatric Dentistry* (2019): 10.5005/jp-journals-10005-1622

## INTRODUCTION

It is very important that a dentist should know the occlusal relationship of primary dentition so that any malocclusion in permanent dentition can be predicted at early stages and corrected accordingly by orthodontic treatments because primary dentition is the stepping stones for permanent dentition.<sup>1</sup> The second most common of the dental diseases in children and young adults next to dental caries is malocclusion.<sup>2</sup> It has been reported that the prevalence of malocclusion in India varies from 20 to 43%.<sup>3</sup> The permanent dentition occlusion can be predicted by observing the key features of occlusion in the child's dentoalveolar system and the key features are the primary molar and canine relationships and spacing in primary dentition. The characteristic set of features of this dentition to a large extent lays the foundation for proper eruption and alignment of the succeeding dentition.<sup>4</sup> There is more prevalence of mesial step as age increases, whereas the prevalence of flush terminal plane shows corresponding a decrease in frequency. Therefore, around 6 years of age, the mesial step predominates at the flush terminal plane, providing a favorable molar relationship in the primary dentition for a direct intercuspation of the erupting permanent molars. The skeletal growth pattern results from the dental adjustment mechanisms; hence, a distal step in the primary dentition will probably show a skeletal imbalance, and eventually results in a class II malocclusion in the permanent dentition.<sup>5</sup> Proffit showed that class III malocclusion is much less common than class II malocclusion, but children who have a mesial step relationship at an early age are more prone to develop a class III malocclusion.<sup>6</sup> The relationship between deciduous canines is also a reliable reference criterion

<sup>1,2</sup>Department of Pedodontics, Saveetha Dental College, Chennai, Tamil Nadu, India

**Corresponding Author:** Deepa Gurunathan, Department of Pedodontics, Saveetha Dental College, Chennai, Tamil Nadu, India, Phone: +91 9994619386, e-mail: drgdeepa@yahoo.co.in

**How to cite this article:** Kumar D, Gurunathan D. Primary Canine and Molar Relationships in Centric Occlusion in 3 to 6-year-old Children: A Cross-sectional Survey. *Int J Clin Pediatr Dent* 2019;12(3):201–204.

**Source of support:** Nil

**Conflict of interest:** None

for the assessment of the anteroposterior occlusion, especially if the second primary molars are missing.<sup>7</sup> Bouge in 1908 stated that if malocclusions were found in the primary dentition, the same occlusal problems would be expected to occur in the succeeding permanent dentition.<sup>8</sup> A spaced primary dentition is an indicator of the favorable development of permanent dentition.<sup>9</sup> These deciduous spaces are a prerequisite to compensate for the discrepancy between the tooth sizes of primary and permanent dentitions, and play a critical role in the later eruption of permanent teeth and the establishment of occlusion.<sup>10</sup> Additionally, a lack of these spaces in deciduous dentition may result in disproportionate jaw and tooth sizes.<sup>11</sup> Spacing in the primary dentition can be subdivided into two types: primate space and developmental space.<sup>12</sup> Primate spaces are located between the lateral incisors and canines in the upper arch, and between the first molars and canines in the lower arch, whereas developmental spacing (also called interdental spacing) is found between the incisors in both

the upper and lower arches.<sup>13</sup> The reason of this study was to assess the occlusal relationships between the primary canine and the primary molar in the primary dentition in centric occlusion and also spacing in primary dentition among a group of 3- to 6-year-old children.

**MATERIALS AND METHODS**

The cross-sectional survey was based on examination of the primary dentition of 100 school children aged 3–6 years from Chennai, Tamil Nadu, India. Approval to conduct this study was obtained from the University Board of Saveetha Dental College and the research duration was 4 months.

The examination was done using pen light and mouth mirror. The age of the child was obtained from school records. The occlusal assessment was done only on children who are healthy and free from extensive caries that would affect the mesiodistal or occlusogingival dimension of a tooth and, therefore, influence the occlusal characteristics.

The primary molar relationship and the canine relationship were assessed using Foster and Hamilton criteria with the teeth in centric occlusion.<sup>13</sup>

Primary molar relationship (terminal plane): the relationship of the maxillary and mandibular second primary molars in the vertical plane.

Flush terminal plane: the distal surfaces of upper and lower primary second molars are in one line with each other when the primary teeth are in occlusion.

Distal step: the distal surface of lower primary second molar is distal to the distal surface of the primary upper second molar in occlusion.

Mesial step: the distal surface of lower primary second molar is mesial to the distal surface of the upper primary second molar in occlusion.

Primary canine relationship:

Class I: the cusp tip of the upper primary canine is in the same vertical plane as the distal surface of the lower primary canine.

Class II: the cusp tip of the upper primary canine tooth is mesial to the distal surface of the lower primary canine.

Class III: the cusp tip of the upper primary canine is distal to the distal surface of the lower primary canine.

**RESULTS**

This study was conducted among 100 school children of age group 3 to 6 years from which 52% were 6 years age, 29% were 5 years age, 14% were 4 years age, and 5% were 3 years age out of which 56% were boys and 44% were girls.

Figure 1 shows the molar relationships and, out of 100 school children, 56% had mesial step followed by 36% with flush terminal relationship and 8% with distal step relationship.

Figure 2 shows the canine relationship and, out of the 100 school children, 61% of children had class III relationship followed by 27% class I relationship and 12% class II relationship.

Figure 3 shows spacings in primary dentition among 100 school children and it was found that 46% of children had no spacing in the primary dentition and 54% had spacing out of which, 30% of children had spacing in only upper anteriors, 20% had spacing in upper and lower anteriors, and 4% had only in lower anteriors. Out of the 30% in upper anteriors, the most common were the primate spaces between the primary lateral incisor and primary canines.

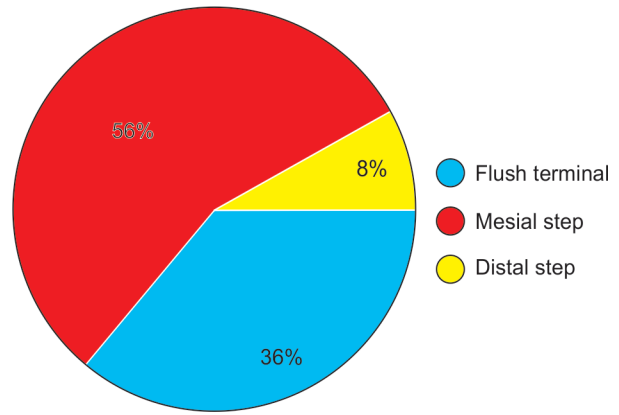


Fig. 1: Molar relationship in primary dentition among 100 school children

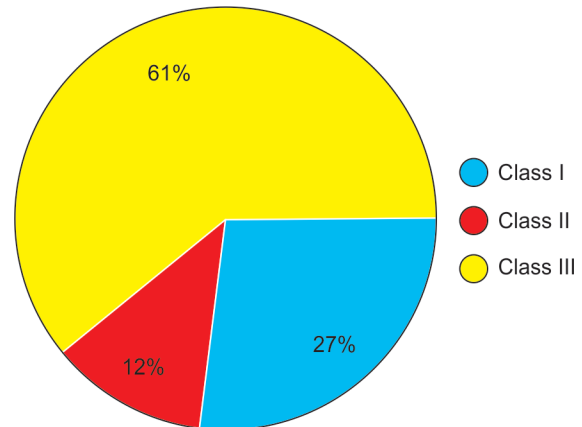


Fig. 2: Canine relationship in primary dentition among 100 school children

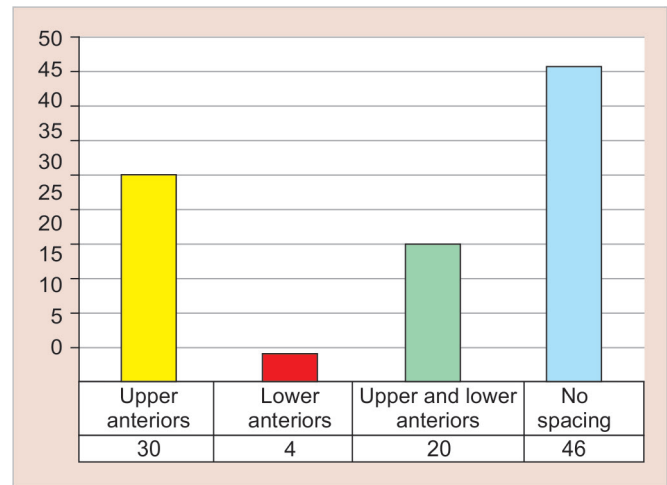


Fig. 3: Spacing in primary dentition among 100 school children

**DISCUSSION**

**Primary Molar Relationship**

Malocclusion in permanent dentition can be predicted in early ages if the occlusion in primary dentition is examined and followed up. In our study, the occlusion in primary dentition is determined by determining the primary molar and primary canine relationship. The molar relationship was observed to be mesial step among 56%



of the examined children. This result was in contrary to the study conducted by Yilmaz et al.'s which showed 88.29% of the flush terminal relationship among 3- to 6-year-old Turkish children.<sup>14</sup> This may be because more a number of 5 to 6-year-old children were included in our study. Our study was in accordance with the study conducted by Gençay et al.'s where there was no prevalence of mesial step in 4- to 4-year-old children but the prevalence of mesial step statistically showed a significant increase ( $p < 0.05$ ) among 5- to 6-year-old children.<sup>15</sup> The reason for an increase in the mesial step frequency may be the growth of the mandible in the anterior direction.<sup>16</sup>

Bishara et al. evaluated the changes that occur during the passage from the primary second molar relationship to permanent first molar relationship. They stated in the cases showing flush terminal planes in the primary dentition, 56% class I and 44% class II relationships developed in the permanent dentition. Since a flush terminal plane in the primary dentition may cause unwanted molar relationships in the permanent dentition, they advised that these cases should be observed to engage them in early orthodontic treatment, if necessary. They observed when distal step existed in the primary dentition, a class II molar relationship occurred in the permanent dentition; therefore, the treatment should be started at an early stage because self-treatment would not be possible. They noted when mesial step existed in primary dentition, the occurrence of a class I relationship would be more and class II relationship would be less frequent in the permanent dentition. Moreover, they stated the occurrence of class III molar relationship in the permanent dentition would be the result of the magnitude of the mesial step.<sup>17</sup> In our study, the prevalence of flush terminal (36%) and the distal step (8%) relationship were less when compared to mesial step; hence, the chance of developing class I relationship in permanent dentition is high when compared to class II and III molar relationship in permanent dentition.

### Primary Canine Relationship

In our study, the canine relationship and out of the 100 school children were found to be as 61% class III relationship followed by 27% class I relationship and 12% class II relationship. These results were in contrary to the study conducted by Yilmaz et al. which showed 87.8% with class I canine relationship in all age groups.<sup>14</sup> Similar studies conducted by Farsi et al. showed 57% with class I canine relationship<sup>16</sup> and Otuyemi et al. showed 74.5% class I canine relationship.<sup>8</sup> This may be because our study population included more number of 5- to 6-year-old children. The 3 and 4-year-old groups demonstrated no class III primary canine relationship, whereas in 5- and 6-year-old children a significant increase in this relationship with an increase in age was observed.<sup>10</sup>

### Spacing

Our study showed that 46% of children had no spacing in the primary dentition and 54% had spacing out of which, 30% of children had spacing in only upper anteriors, 20% had spacing in upper and lower anteriors, and 4% had only in lower anteriors. Out of the 30% in upper anteriors, the most common were the primate spaces between the primary lateral incisor and the primary canine which were similar to the study conducted by Otuyemi et al. which showed that the most common site of spacing was mesial to maxillary canines.<sup>8</sup> Primate space and leeway space are normal in deciduous dentition. A similar study showed that primate spaces were frequently found in the maxilla than in the mandible and

male children demonstrated more frequency of primate spaces than females.<sup>18-21</sup> This was in accordance with our study which shows that primate spaces are more common in the upper arch but our study does not include spacing in gender distribution. The gender distribution was not included because a similar study showed no significant difference between the genders in Tehran and Saudi children.<sup>22,23</sup>

### CONCLUSION

From our study, we conclude that the mesial step primary relationship was more common among 5- to 6-year-old children followed by flush terminal relationship and very less distal step relationship. The class III primary canine relationship was more common followed by classes I and II. Spacing was present more common in upper anteriors among which the most common were the primate spacing.

### REFERENCES

1. Ferreira RI, Alves AC, et al. Prevalence of normal occlusal characteristics on deciduous dentition. *J Dent Res* 2000;79:1159.
2. Parmesh H, Mathur VP. National Oral Health Care Program. *Indian Pediatr* 2002;39:1001-1005.
3. Babu AM, Chandu GN, et al. Prevalence of malocclusion and orthodontic treatment needs among 13-15 year old school going children of Davangere City, Karnataka, India. *J Indian Assoc Public Health Dent* 2005;6:32-35.
4. Ravn JJ. Longitudinal study of occlusion in the primary dentition in 3-7 year old children. *Scand J Dent Res* 1980;88:165-170. DOI: 10.1111/j.1600-0722.1980.tb01210.x.
5. Nanda RS, Khan I, et al. Age changes in the occlusal pattern of deciduous dentition. *J Dent Res* 1973 Mar-Apr;52(2):221-224. DOI: 10.1177/00220345730520020601.
6. Proffit WR. A textbook of contemporary orthodontics, 2nd ed, Mosby Year Book International, 1993.
7. Saravanan S, Madivanan I, et al. Prevalence pattern of dental caries in the primary dentition among school children. *Indian J Dent Res* 2005;16(4):140-146. DOI: 10.4103/0970-9290.29907.
8. Otuyemi OD, Sote EO, et al. Occlusal relationships and spacing or crowding of teeth in the dentitions of 3-4-year-old Nigerian children. *Int J Paediatr Dent* 1997 Sep;7(3):155-160. DOI: 10.1046/j.1365-263X.1997.00232.x.
9. Vinay S, Keshav V, et al. Prevalence of spaced and closed dentition and its relation to malocclusion in primary and permanent dentition. *Int J Clin Pediatr Dent* 2012;5:98-100.
10. Janiszewska-Olszowska J, Stepień P, et al. Spacing in deciduous dentition of Polish children in relation to tooth size and dental arch dimensions. *Arch Oral Biol* 2009;54:397-402. DOI: 10.1016/j.archoralbio.2008.12.008.
11. Baume LJ. Physiological tooth migration and its significance for the development of occlusion. I. The biogenetic course of the deciduous dentition. *J Dent Res* 1950;29:123-132. DOI: 10.1177/00220345500290020301.
12. Alexander S, Prabhu NT. Profiles, occlusal plane relationships and spacing of teeth in the dentitions of 3 to 4 years old children. *J Clin Pediatr Dent* 1998;22(4):329-334.
13. Foster TD, Hamilton MC. Occlusion in the primary dentition. Study of children at 2 and one-half to 3 years of age. *Br Dent J* 1969 Jan 21;126(2):76-79.
14. Yilmaz Y, Şimşek S, et al. Primary Canine and Molar Relationships in Centric Occlusion in Three to Six Year-Old Turkish Children: A Cross-Sectional Study. *J Contemp Dent Pract* 2006 July;7(3):59-66.
15. Gençay K, Aktören O, et al. Türk çocuklarında süt dişi kaviserinin morfolojik olarak incelenmesi. *İÜ Diş Hek Fak Derg* 1995;2:41-45.

16. Farsi NMA, Salama FS. Characteristics of primary dentition occlusion in a group of Saudi children. *Int J Pediatr Dent* 1996;6:253–259. DOI: 10.1111/j.1365-263X.1996.tb00254.x.
17. Bishara SE, Hoppens BJ, et al. Changes in the molar relationship between the deciduous and permanent dentitions: a longitudinal study. *Am J Orthod Dentofac Orthop* 1988;93:19–28. DOI: 10.1016/0889-5406(88)90189-8.
18. Joshi MR, Makhija PG. Some observations on spacing in the normal deciduous dentition of 100 Indian children from Gujarat. *Br J Orthod* 1984;11:75–79. DOI: 10.1179/bjo.11.2.75.
19. Abu Alhajja ESJ, Qudeimat MA. Occlusion and tooth/arch dimensions in the primary dentition of preschool Jordanian children. *Int J Paediatr Dent* 2003;13:230–239. DOI: 10.1046/j.1365-263X.2003.00466.x.
20. Kaufman A, Koyoumdjisky E. Normal occlusal patterns in the deciduous dentition in preschool children in Israel. *J Dent Res* 1967;46:478–482.
21. Ohno N, Kashima K, et al. A study on interdental spaces of the deciduous dental arch in Indian sample. *Aichi Gakuin Daigaku Shigakkai Shi* 1990;28:79–91.
22. Mahmoodian J, Afshar H, et al. Determination of primate Space on 4 to 5 years old children of Tehran's Kindergarten in 2000. *J Dent (Tehran, Iran)* 2004;1:21–26.
23. Salako N, Alamoudi N, et al. Prevalence and distribution pattern of interdental spaces in the primary dentition of Saudi Arabian children. *J King Abdulaziz Univ-Med Sci* 1999;7:107–113. DOI: 10.4197/Med.7-2.11.